

Üst ve Alt Ekstremitte

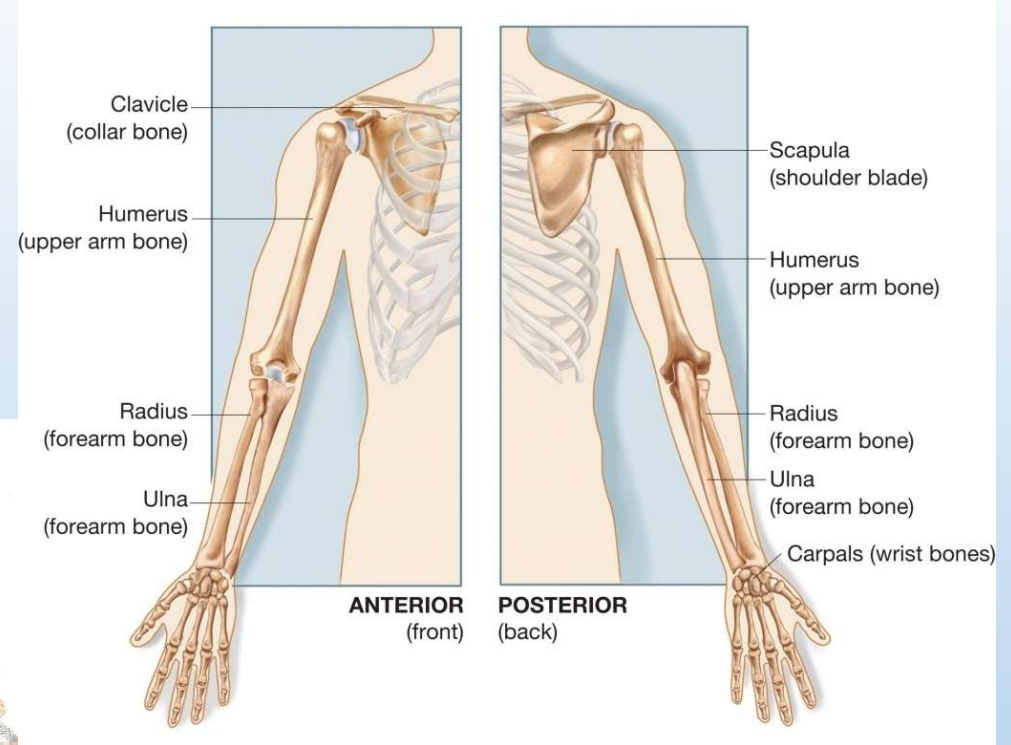
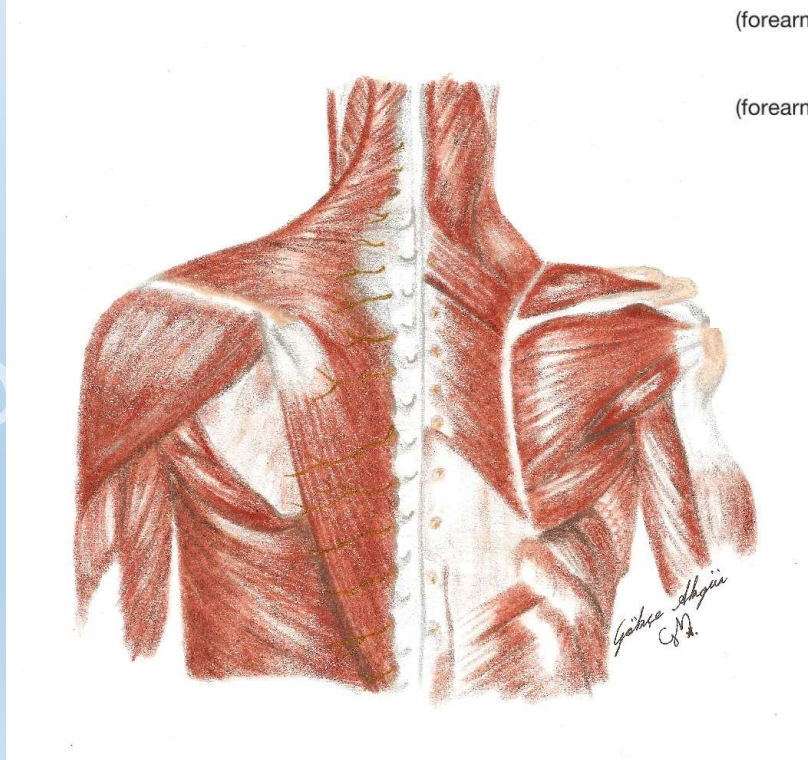
Prof. Dr. Mustafa KARAHAN

Prof.Dr. Mustafa KARAHAN

Üst Ekstremité

- Üst ekstremitéyi oluşturan bölgeler:

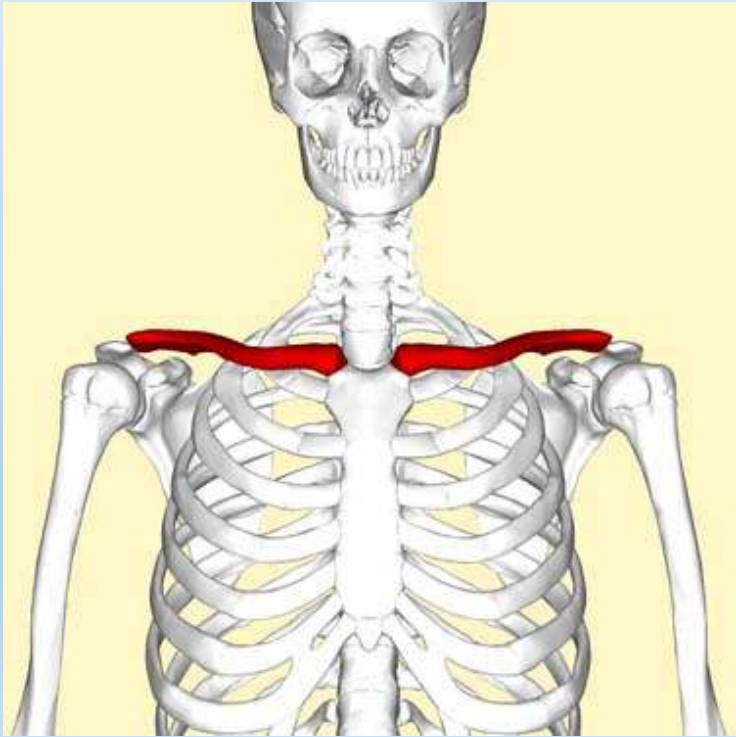
1. Omuz
2. Kol
3. Önkol
4. El bileđi
5. El



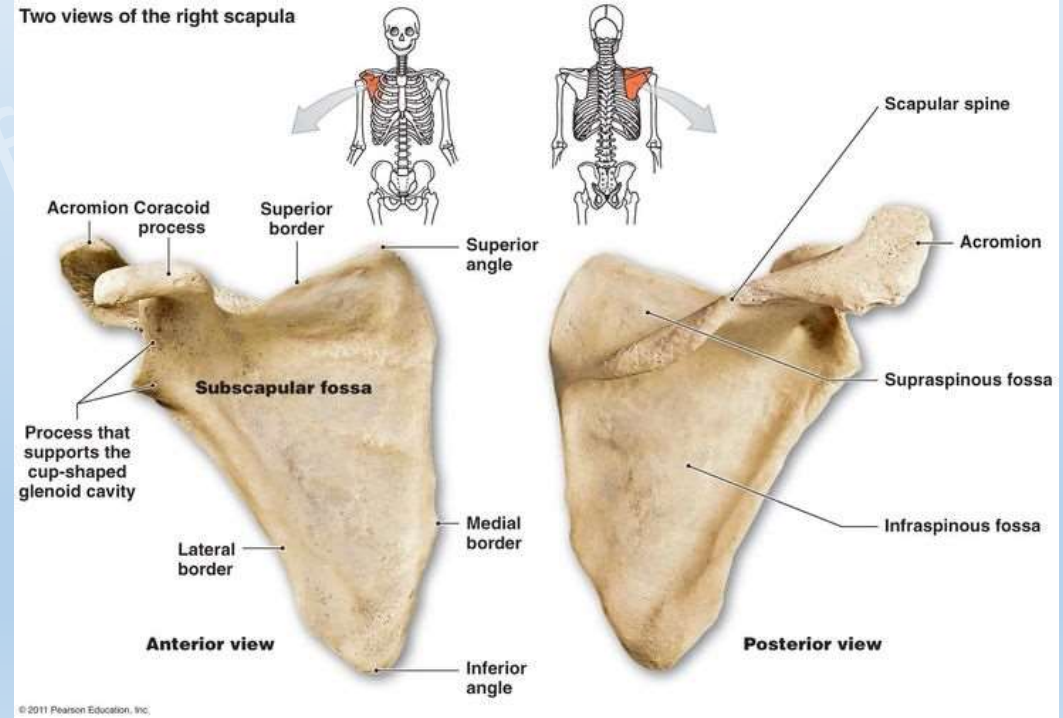
Üst Ekstremit

Omuz bölgesi kemikleri:

- Clavicula



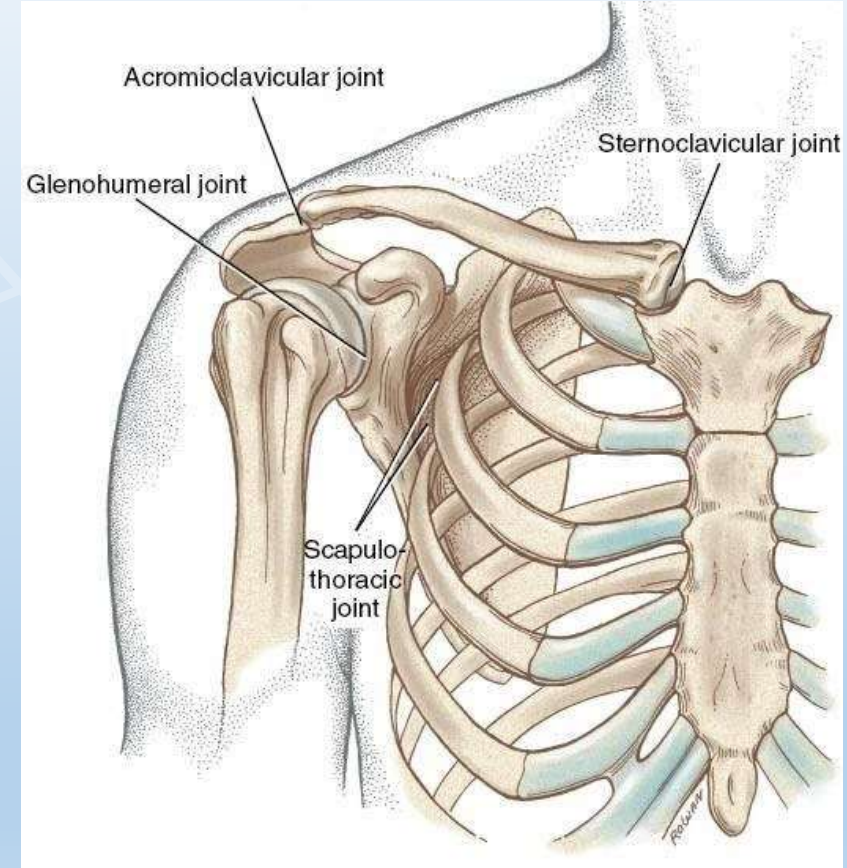
Scapula



Üst Ekstremitite

Omuz Bölgesindeki Eklemler:

1. Sternum + clavícula = Sternoclavicular eklem (SC)
2. Acromion + clavícula = Acromioclavicular eklem (AC)
3. Glenoid çukur + humerus = Glenohumeral eklem (GH)
4. Scapula + toraks = Scapulotorasik eklem (ST)

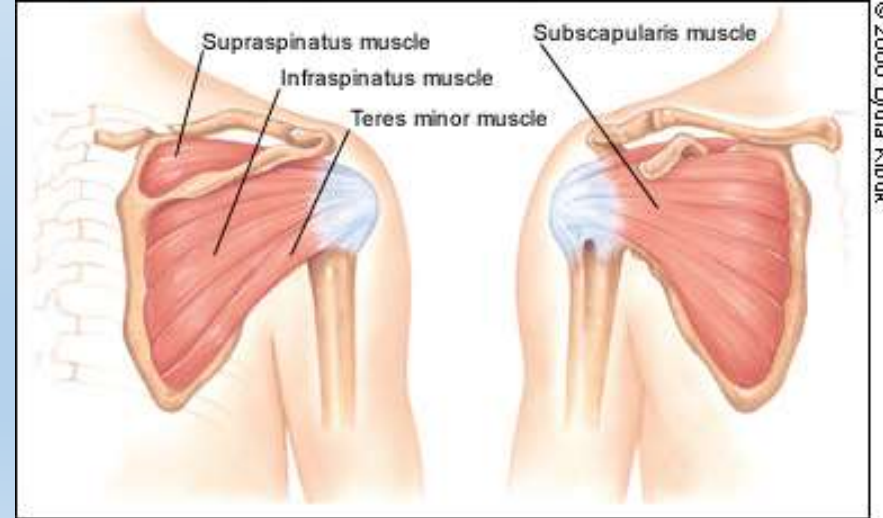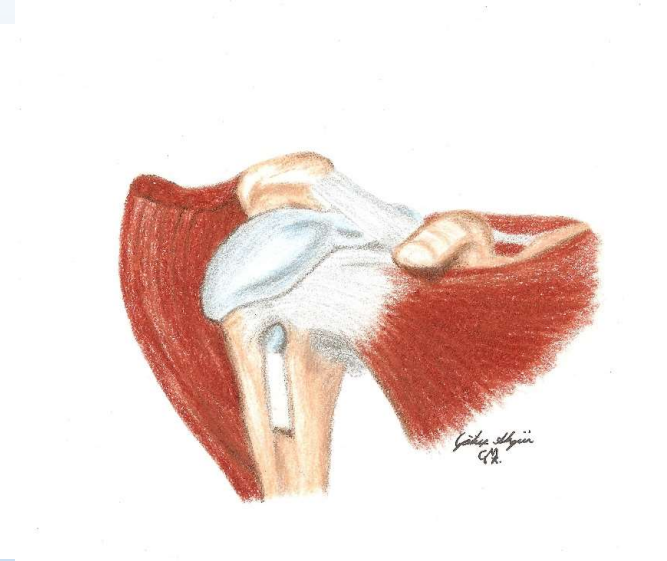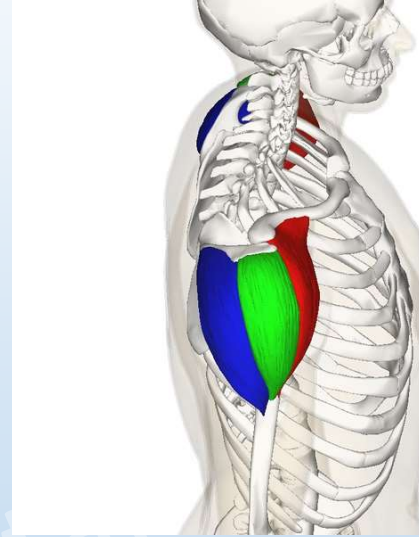


Üst Ekstremité

Omuz bölgesindeki bazı kaslar:

- Deltoideus
- Rotator cuff:
 1. Supraspinatus
 2. Infraspinatus
 3. Teres minör
 4. Subscapularis

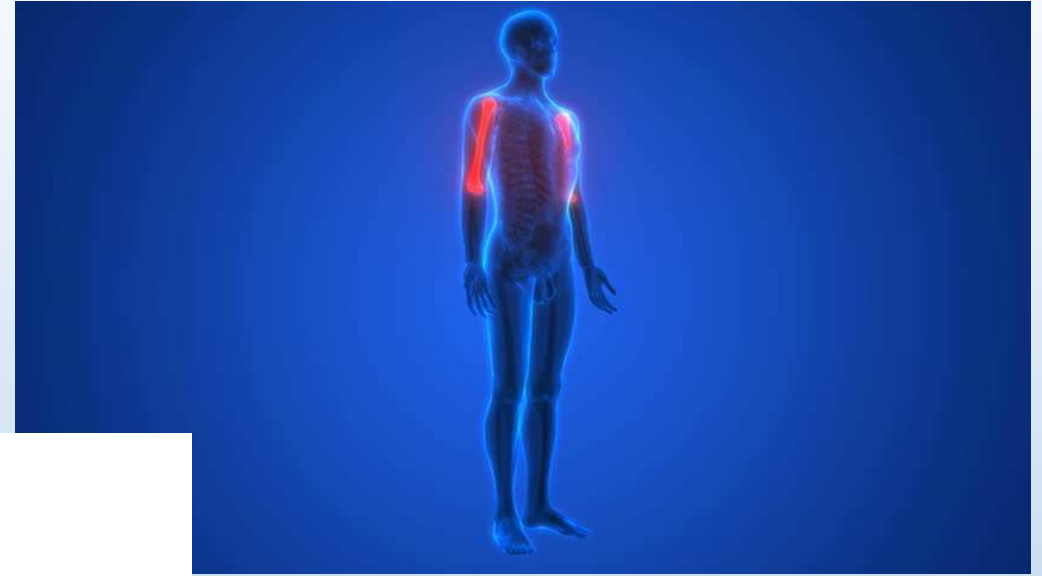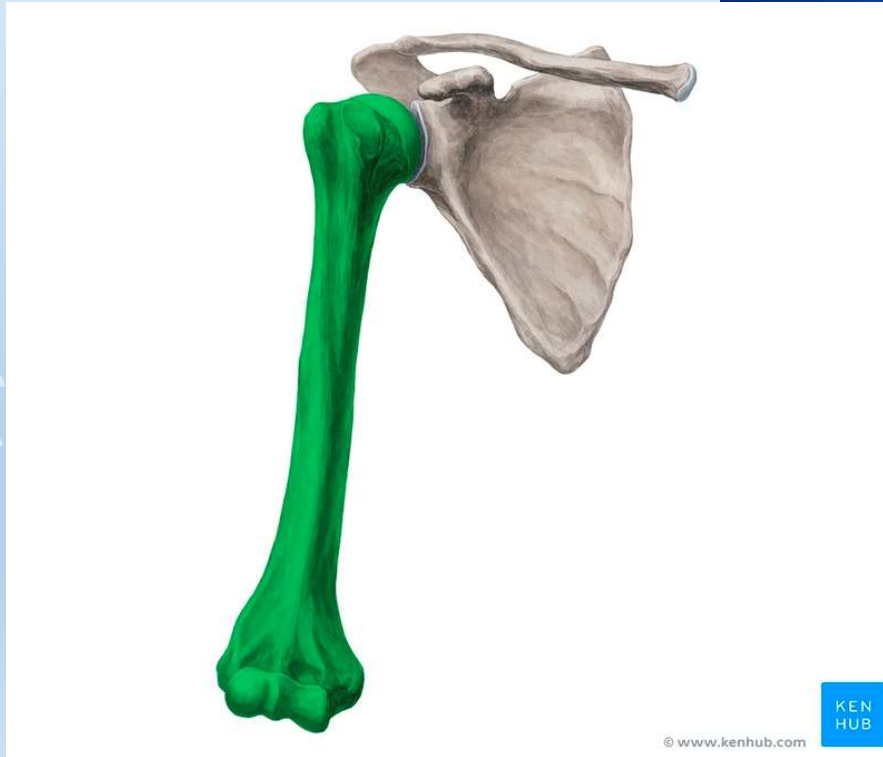<https://www.youtube.com/watch?v=iXadGuuBhJI>



Üst Ekstremit

Kol bölgesi kemiđi:

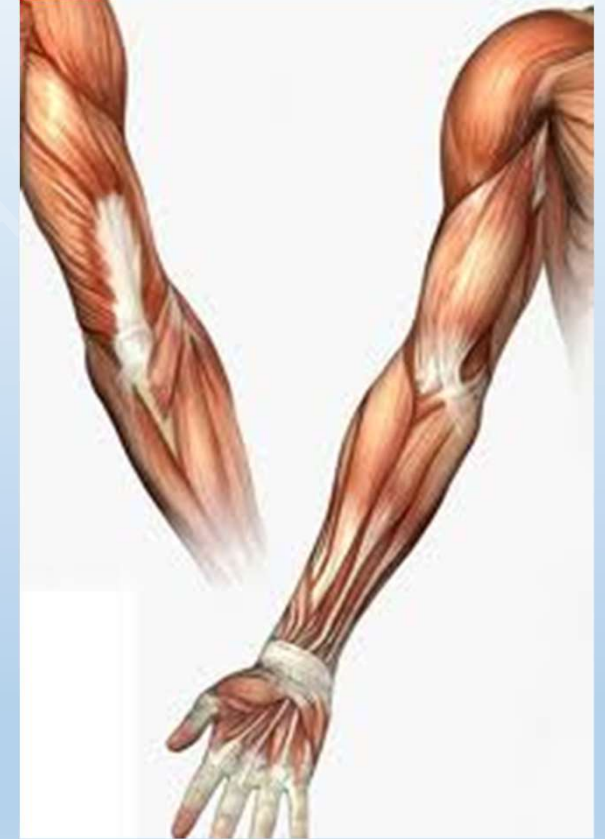
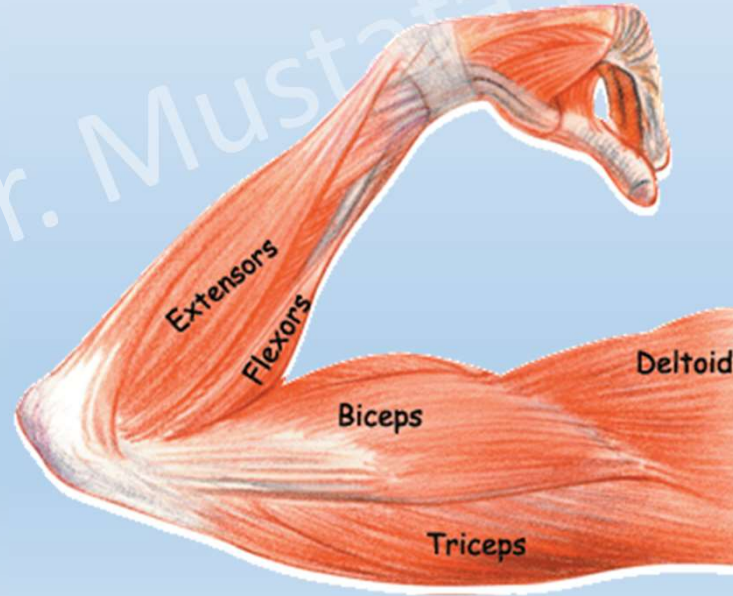
- Humerus



Üst Ekstremité

Kol bölgesindeki bazı kaslar:

- Biceps brachii
- Triceps brachii

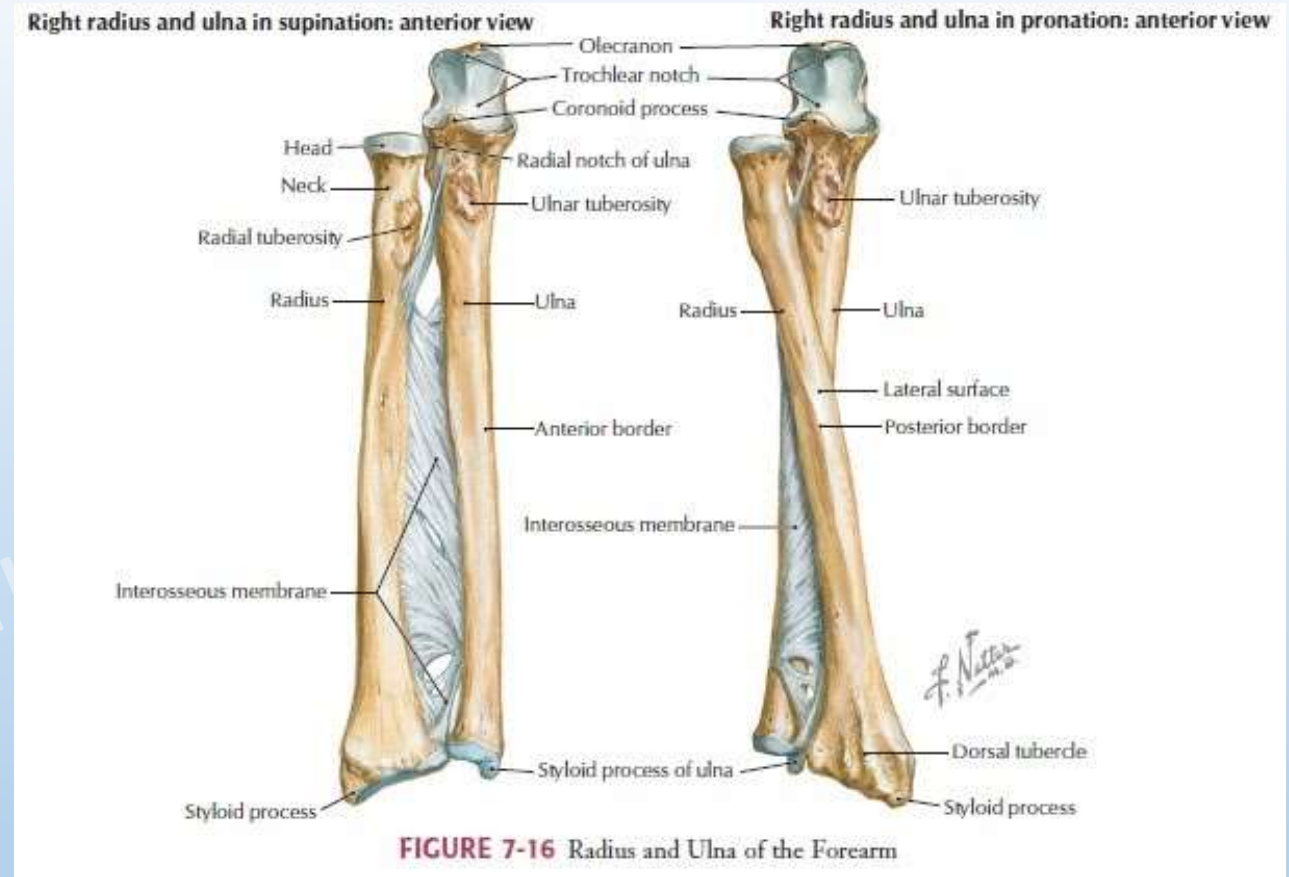


Üst Ekstremité

Önkol bölgesi kemikleri:

- Radius

- Ulna

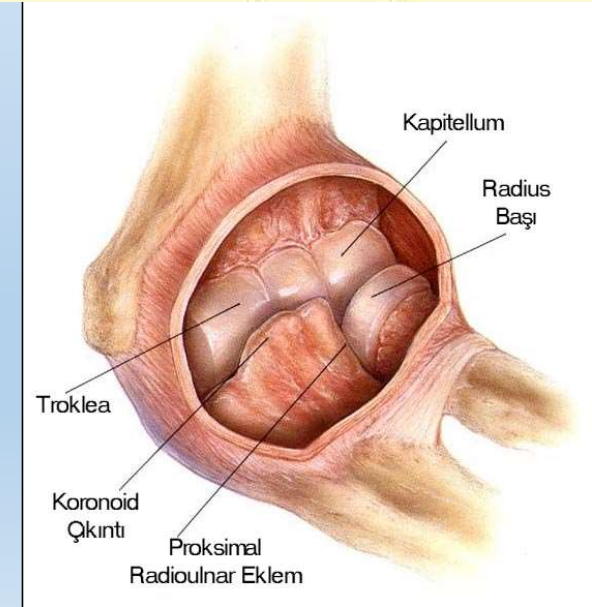
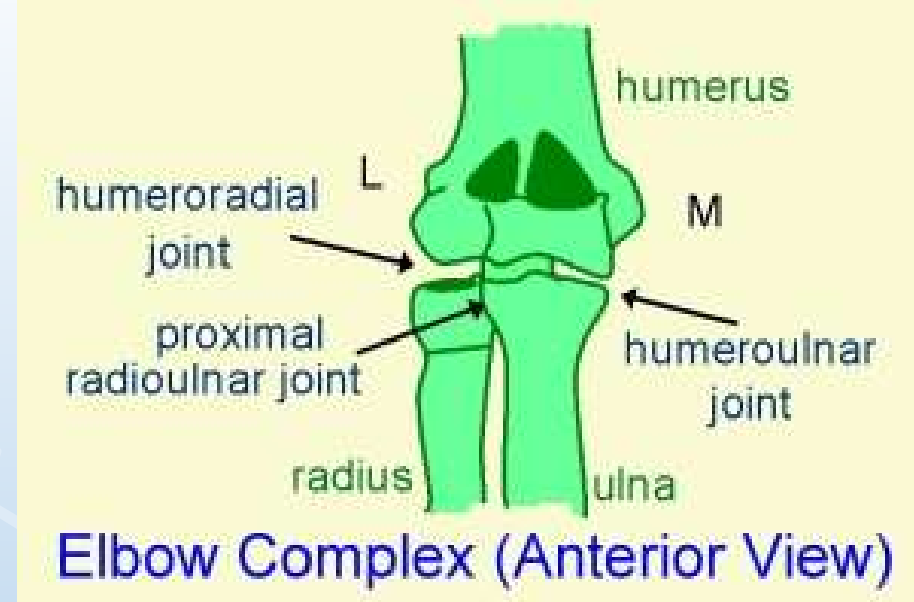

- <https://www.youtube.com/watch?v=DsjFkk6Nuzo>

Üst Ekstremité

Dirsek bölgesindeki eklemler:

1. Humerus + ulna = Humeroulnar eklem
2. Humerus + radius = Humeroradial eklem
3. Radius + proksimal ulna = Proksimal radioulnar eklem

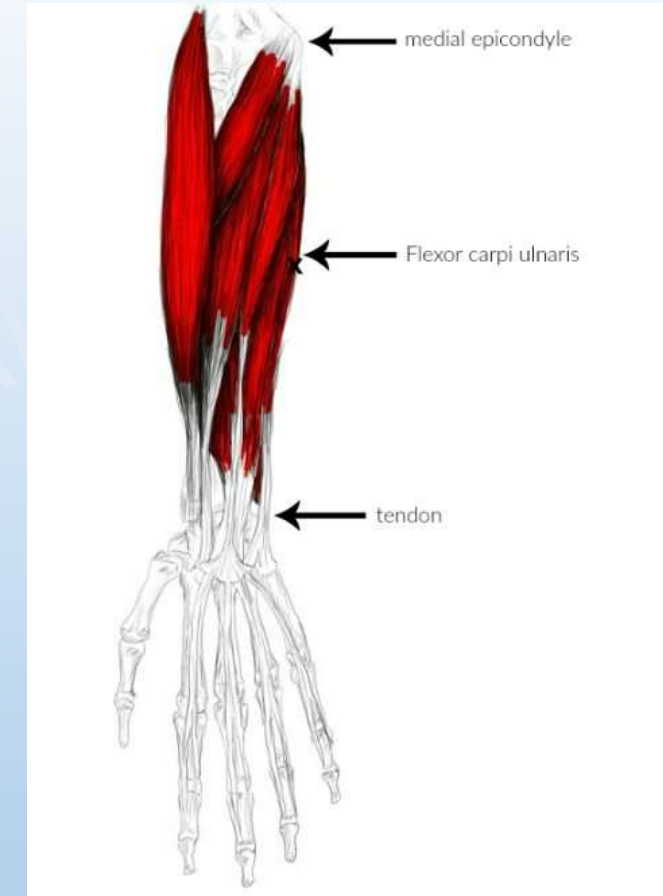
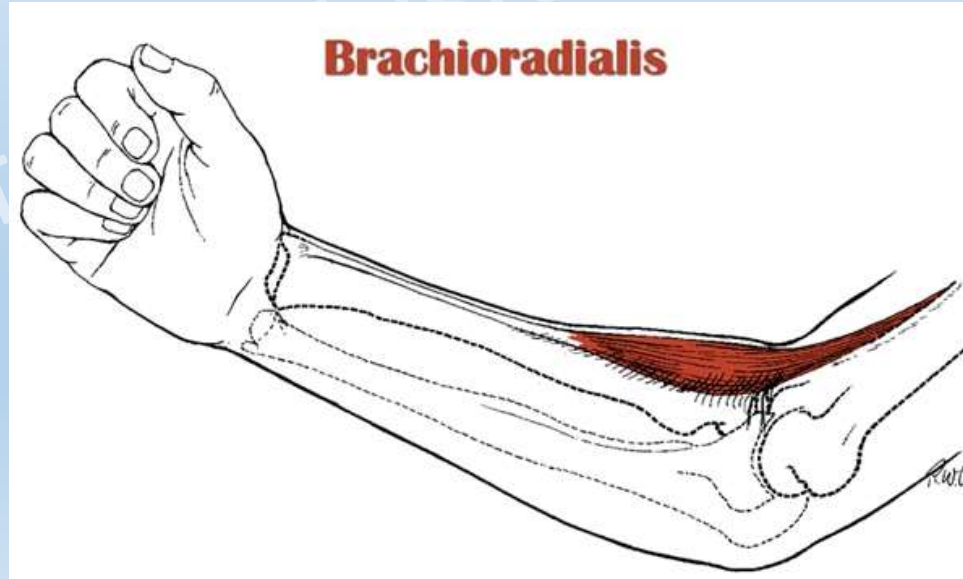


Üst Ekstremité

Önkol bölgesindeki bazı kaslar:

- Fleksör carpi ulnaris

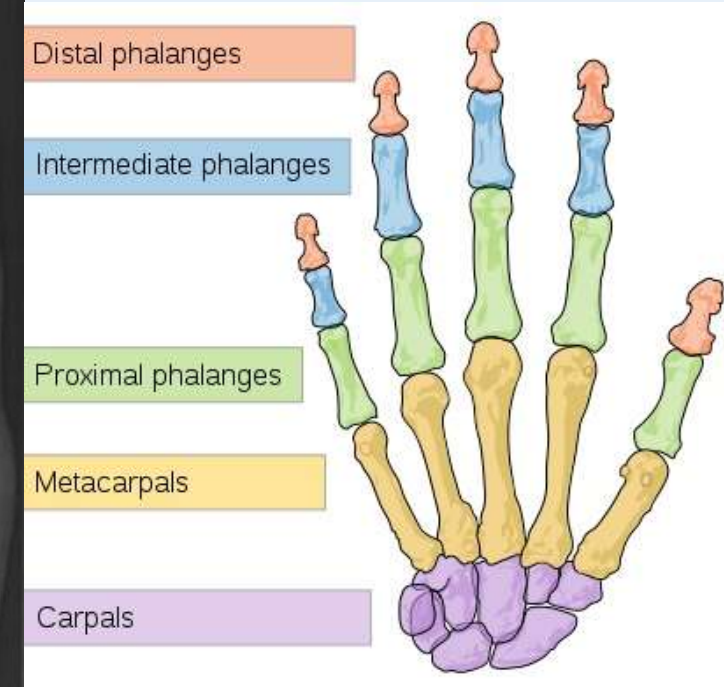
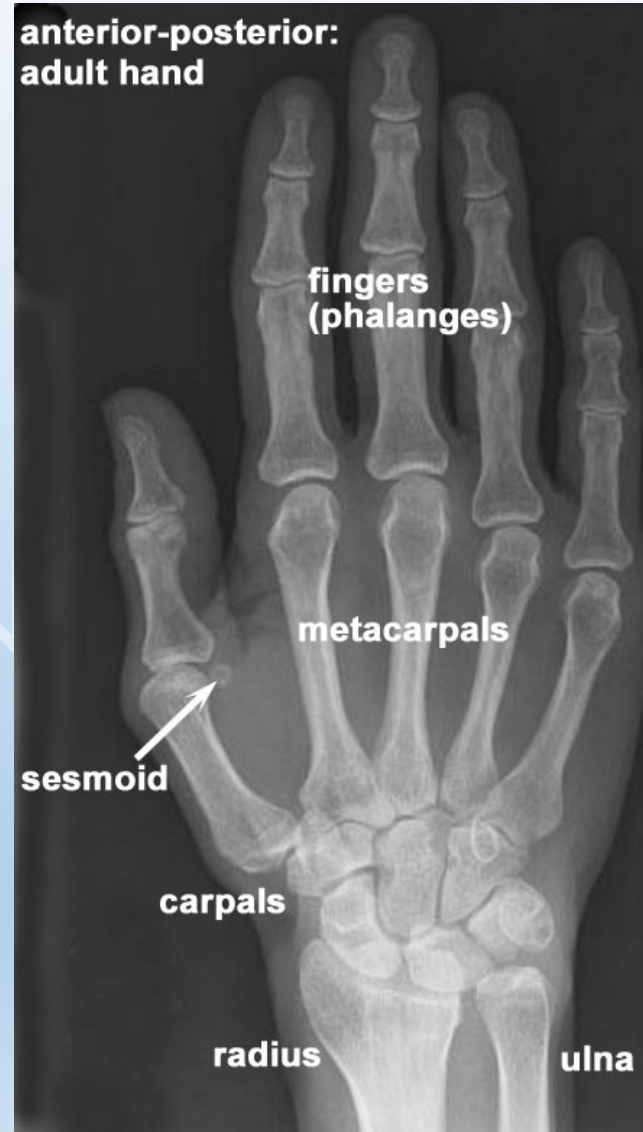- Brachioradialis



Üst Ekstremit

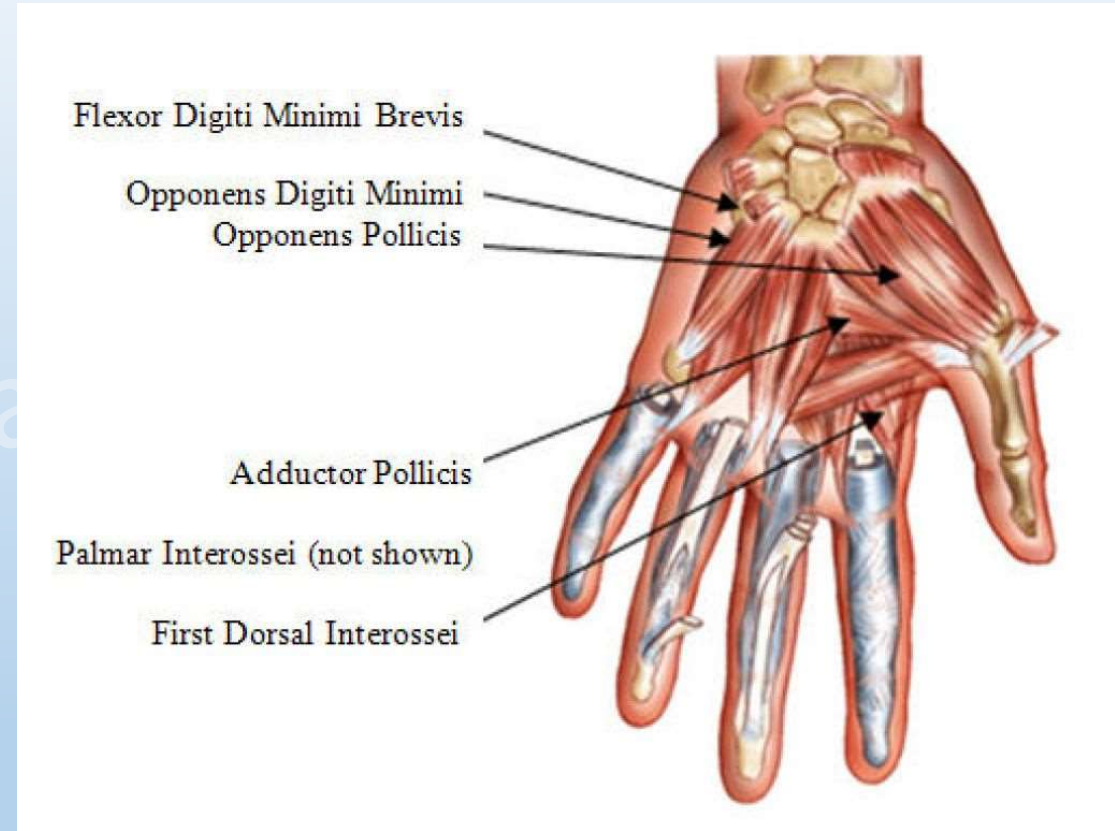
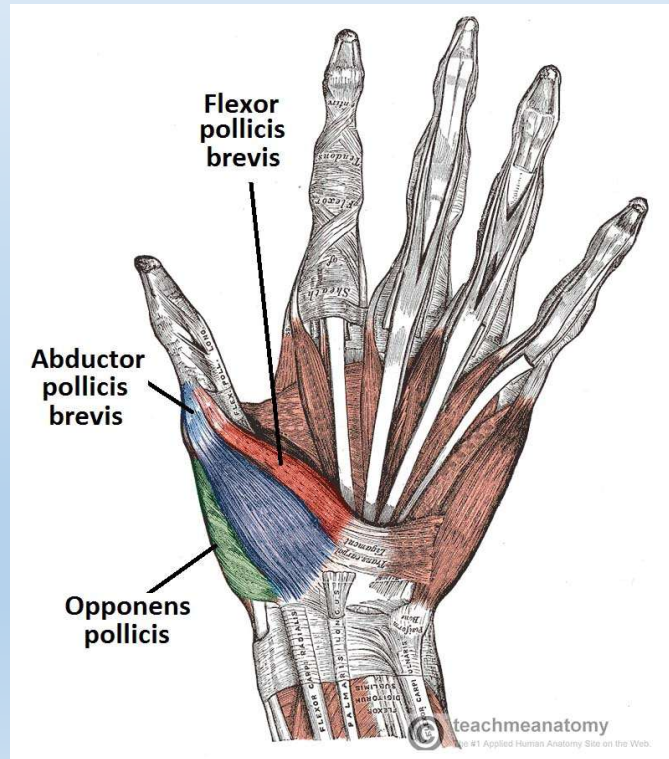
El bölgesi kemikleri:

1. Falankslar: 14 adet
2. Sesamoidler: 2 adet
3. Metakarpaller: 5 adet
4. Karpaller
 - Proksimal sıra: 4 adet
 - Distal sıra: 4 adet



Üst Ekstremité

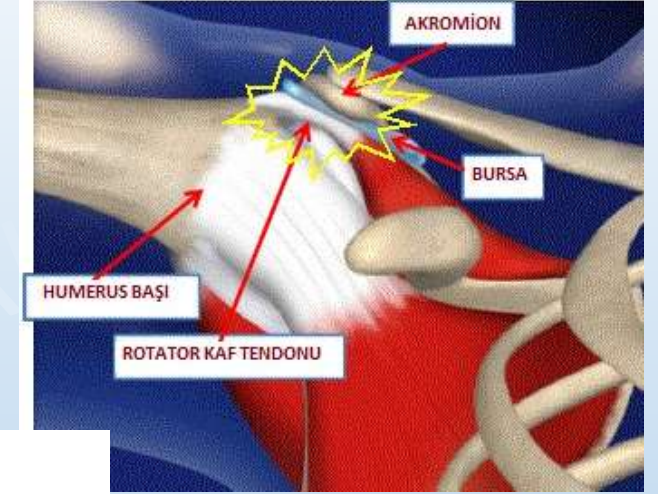
El bölgesindeki bazı kaslar



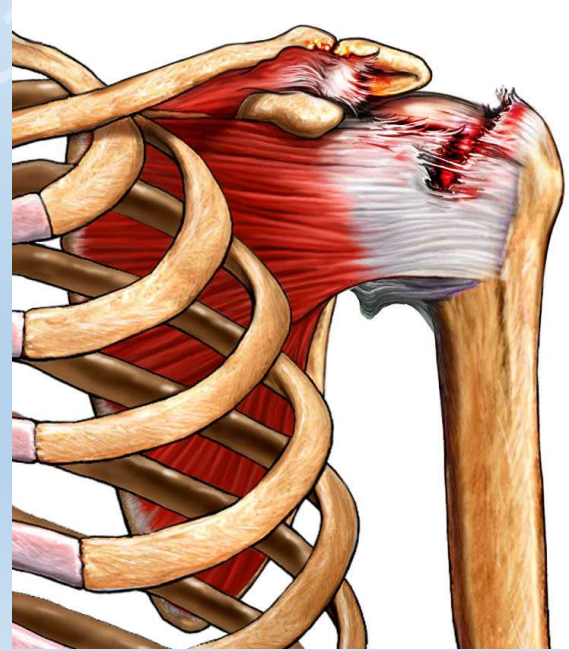
Üst Ekstremitte Yaralanmaları

Omuz bölgesindeki bazı yaralanmalar:

1. Sıkışma (Impingement) sendromu



2. Rotator Cuff (Rotator Manşet) Yırtığı

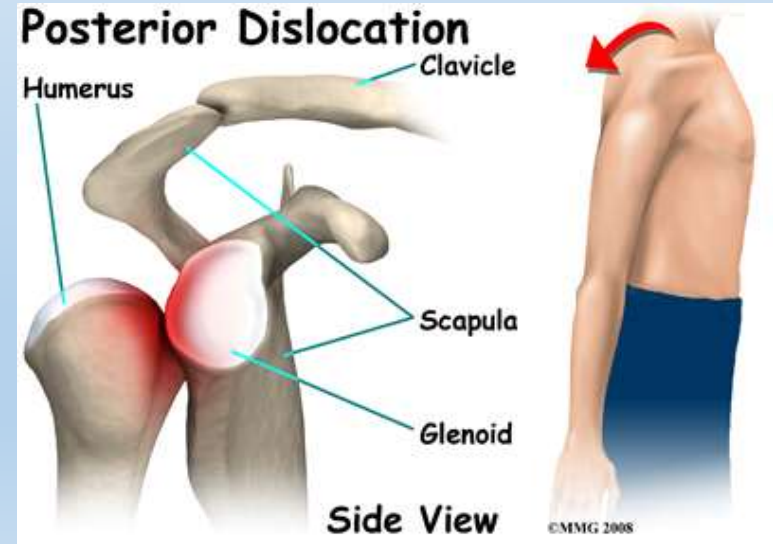
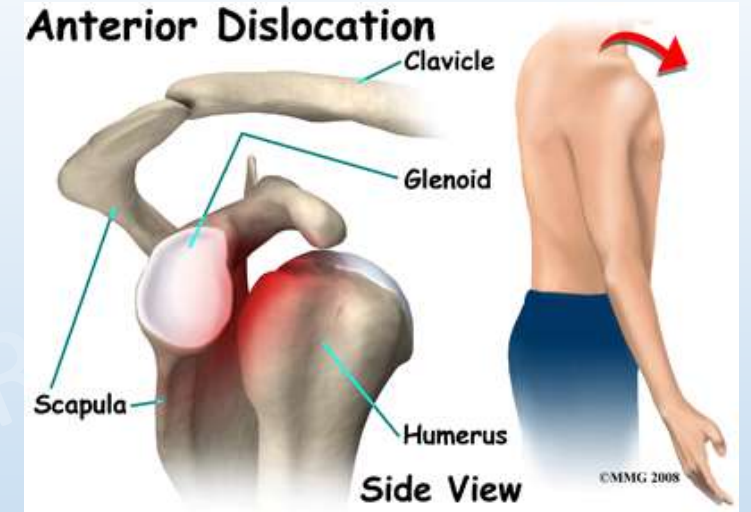


Üst Ekstremitte Yaralanmaları

Omuz bölgesindeki bazı yaralanmalar:

3. Akut Öne Omuz çıkığı (Anterior omuz instabilitesi)

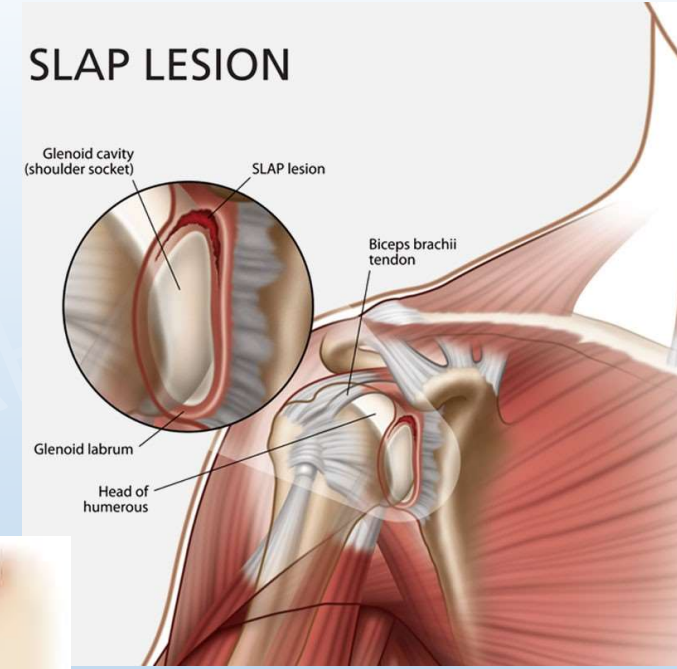
4. Akut Arkaya Omuz çıkığı (Posterior omuz instabilitesi)



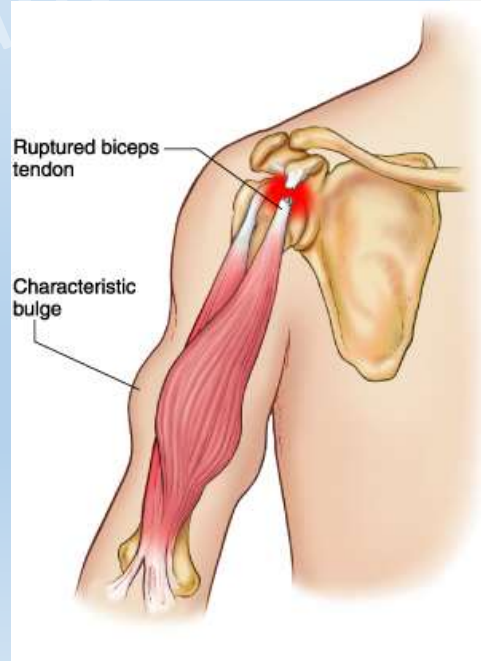
Üst Ekstremitte Yaralanmaları

Omuz bölgesindeki bazı yaralanmalar:

5. SLAP (Superior Labrum Anterior Posterior) Lezyonu



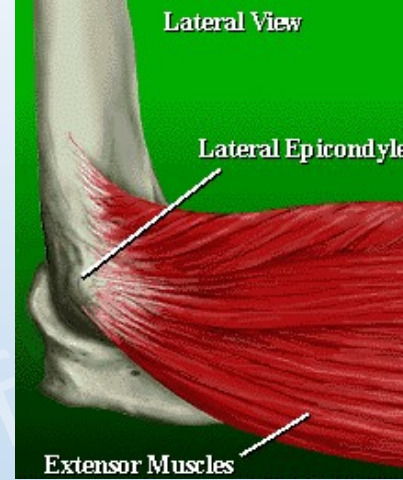
6. Biceps kasının uzun tendonunun kopması



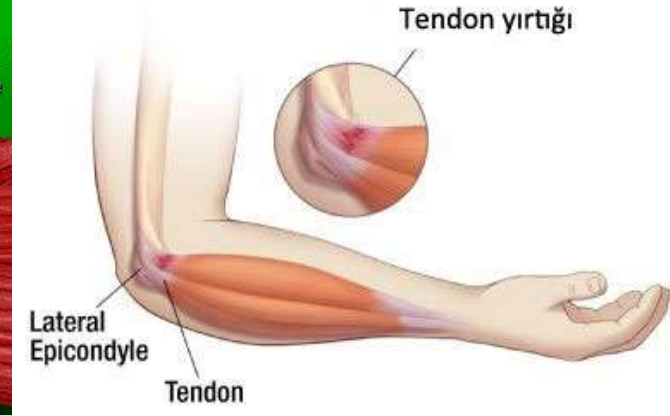Üst Ekstremitte Yaralanmaları

Kol, dirsek ve önkol bölgesindeki bazı yaralanmalar:

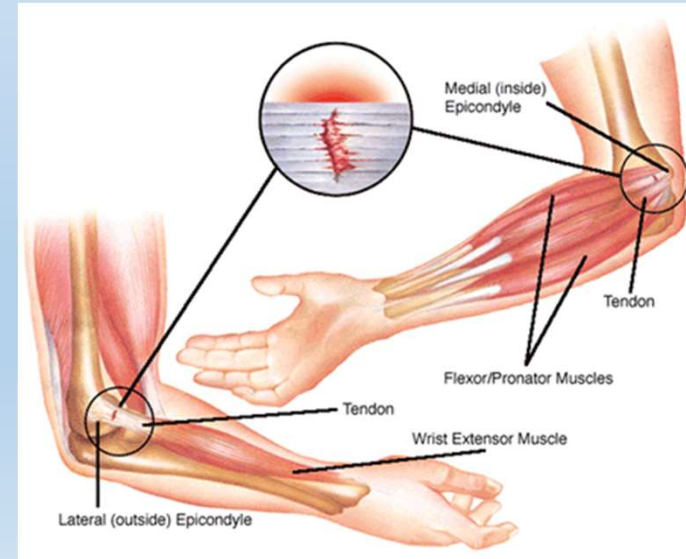
1. Lateral Epikondilit (Tenisçi Dirseği)



Tenisçi Dirseği



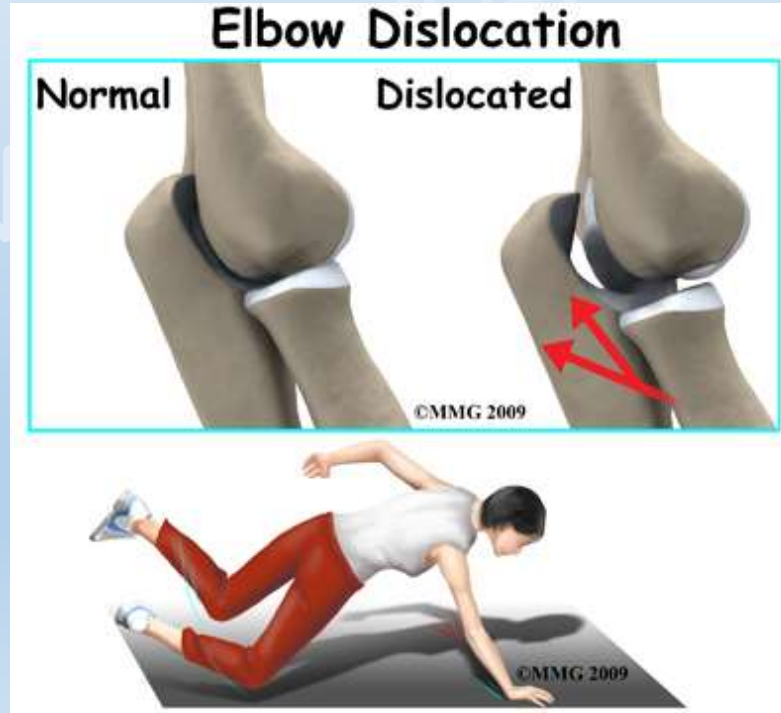
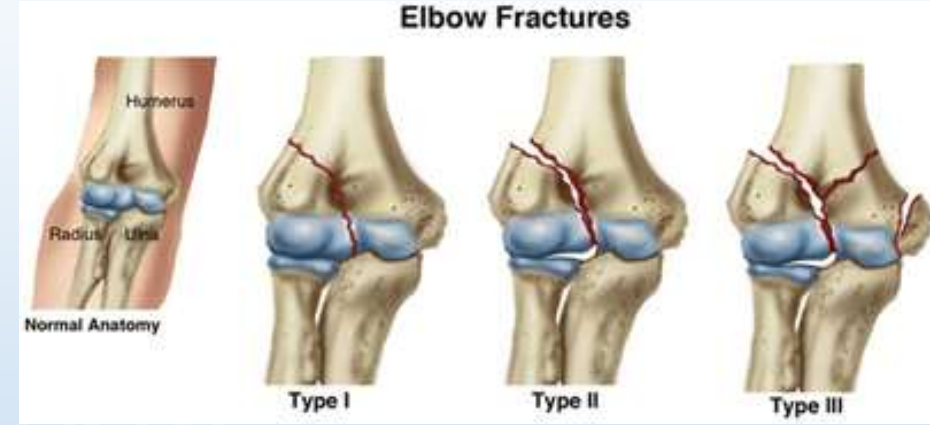2. Medial Epikondilit (Golfçü Dirseği)



Üst Ekstremitte Yaralanmaları

Kol, dirsek ve önkol bölgesindeki bazı yaralanmalar:

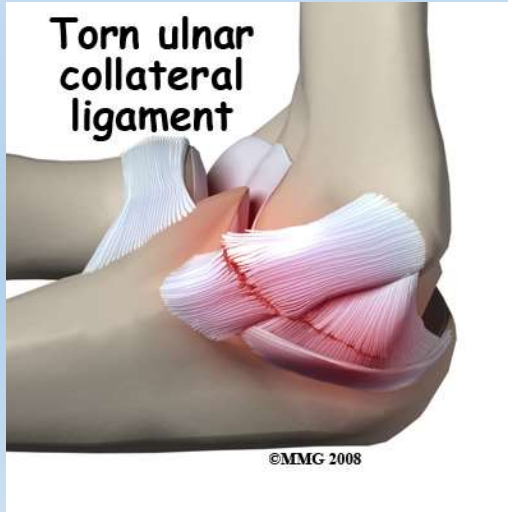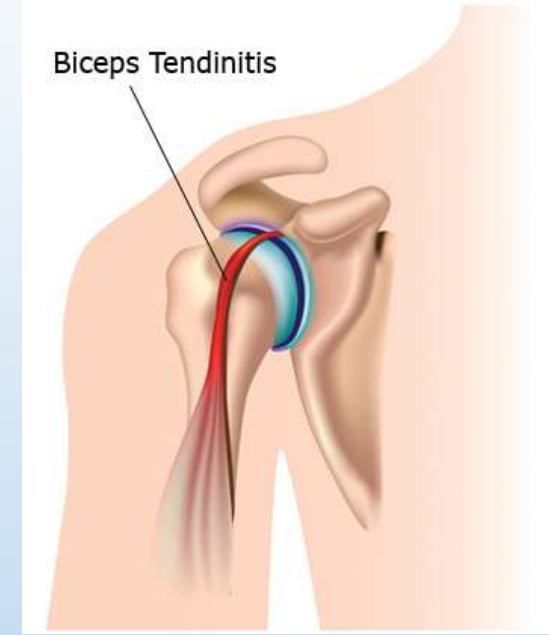
3. Dirsek Kırıkları
4. Dirsek Çıkıkları



Üst Ekstremitte Yaralanmaları

Kol, dirsek ve önkol bölgesindeki bazı yaralanmalar:

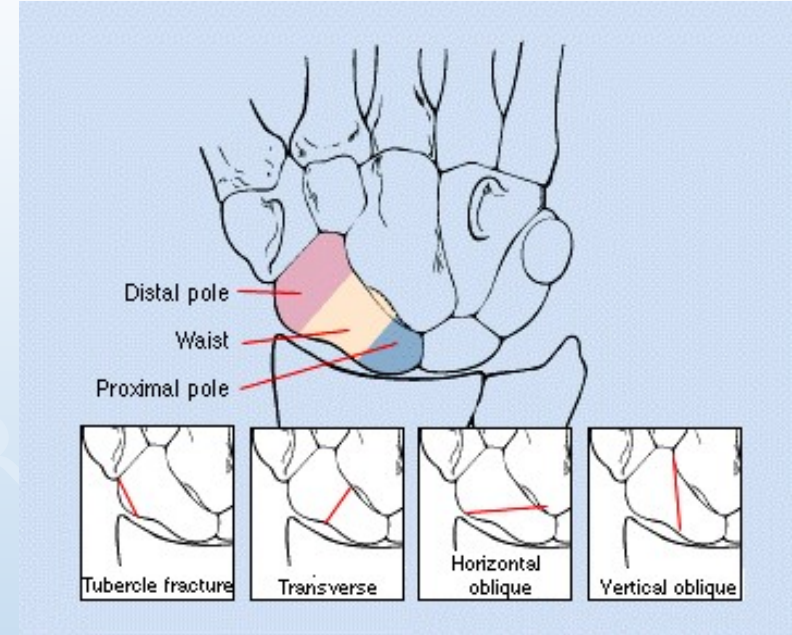
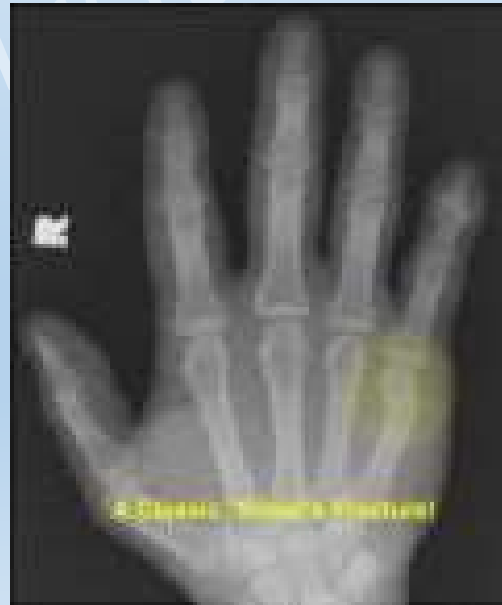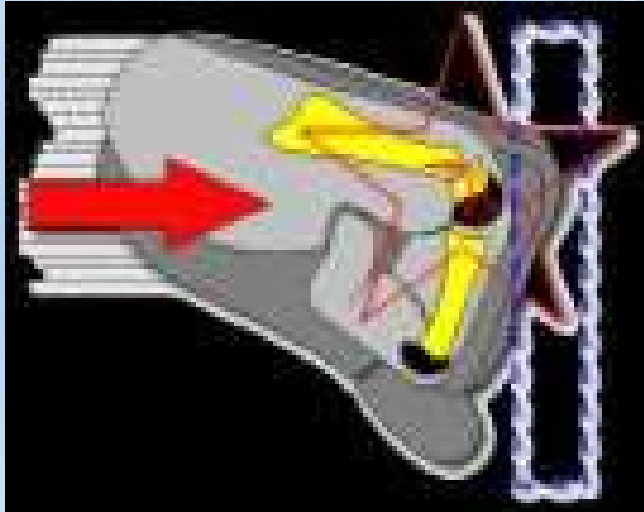
5. Biceps Tendiniti
6. Medial ve Posterolateral Bağ Yaralanmaları



Üst Ekstremitte Yaralanmaları

El bölgesindeki bazı yaralanmalar:

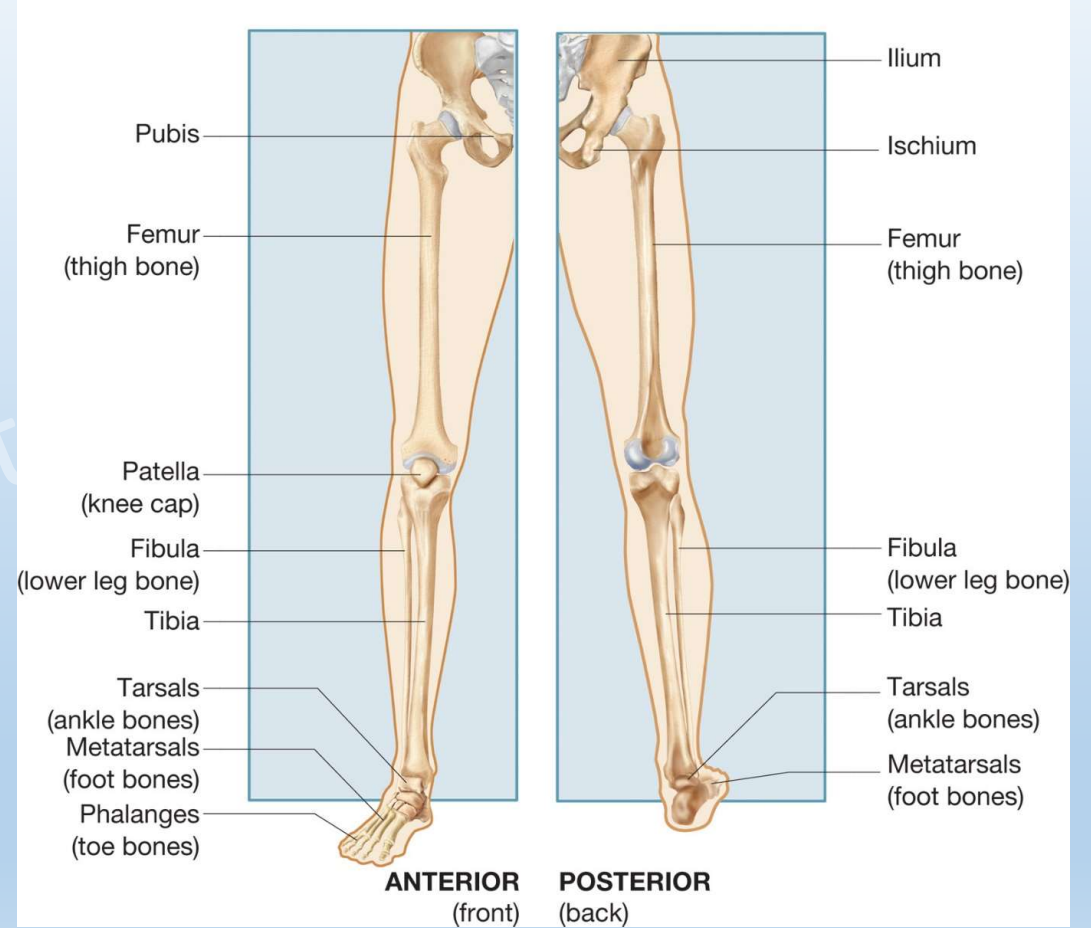
1. Scaphoid kırığı
2. Parmak Kırıkları
 - Boksör kırığı – 5. metakarp kırığıdır.



Alt Ekstremit

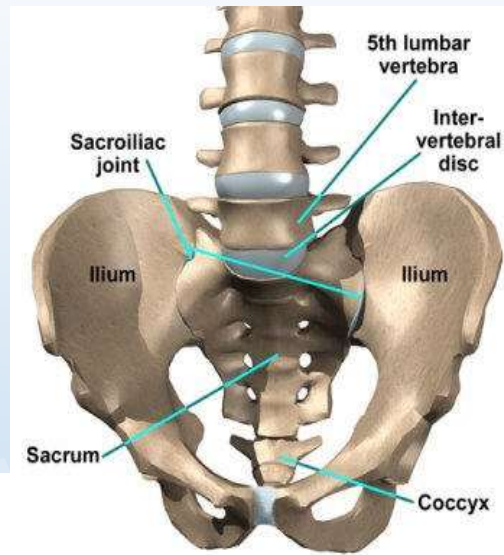
- Alt ekstremitiyi oluşturan bölgeler:

1. Pelvis
2. Uyluk
3. Diz
4. Bacak
5. Ayak bileği
6. Ayak

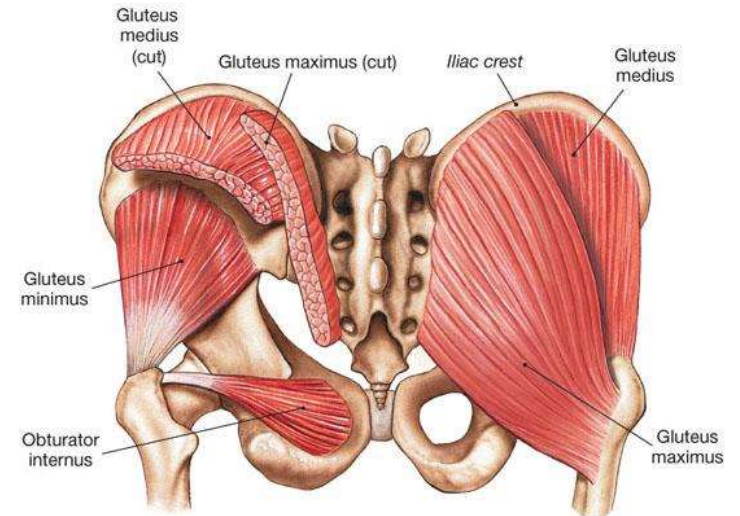
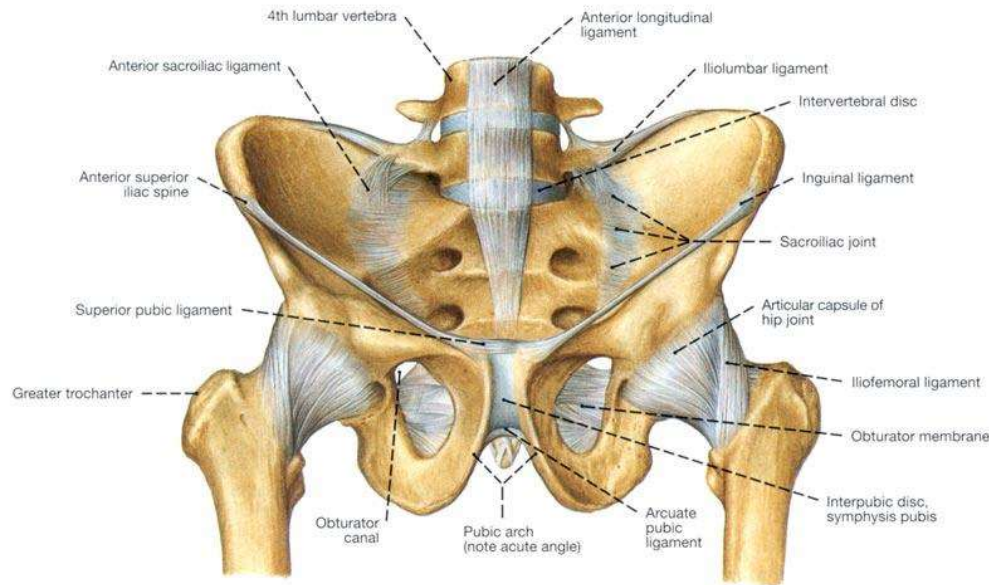


Alt Ekstremit

- Pelvis



Pelvis and Ligaments, Front View, Male

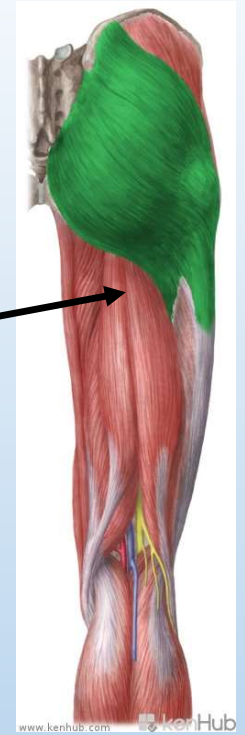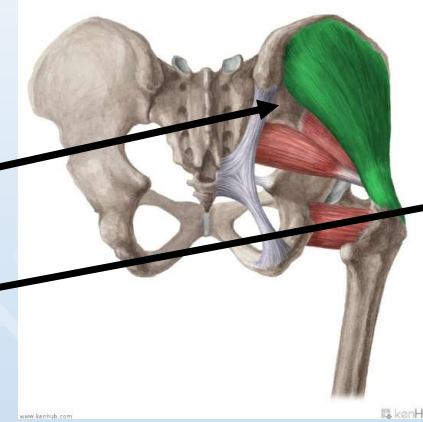
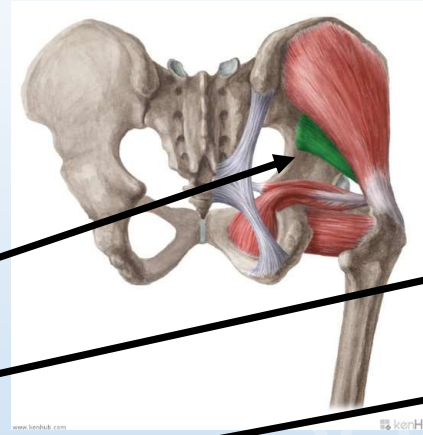


(c) Gluteal and lateral rotators, posterior view

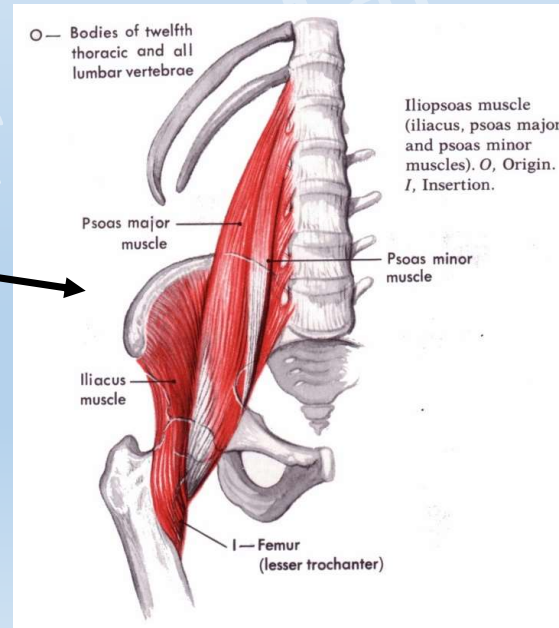
Alt Ekstremit

Pelvis bölgesindeki bazı kaslar:

- Gluteal kaslar:
 1. Gluteus minimus
 2. Gluteus medius
 3. Gluteus maksimus

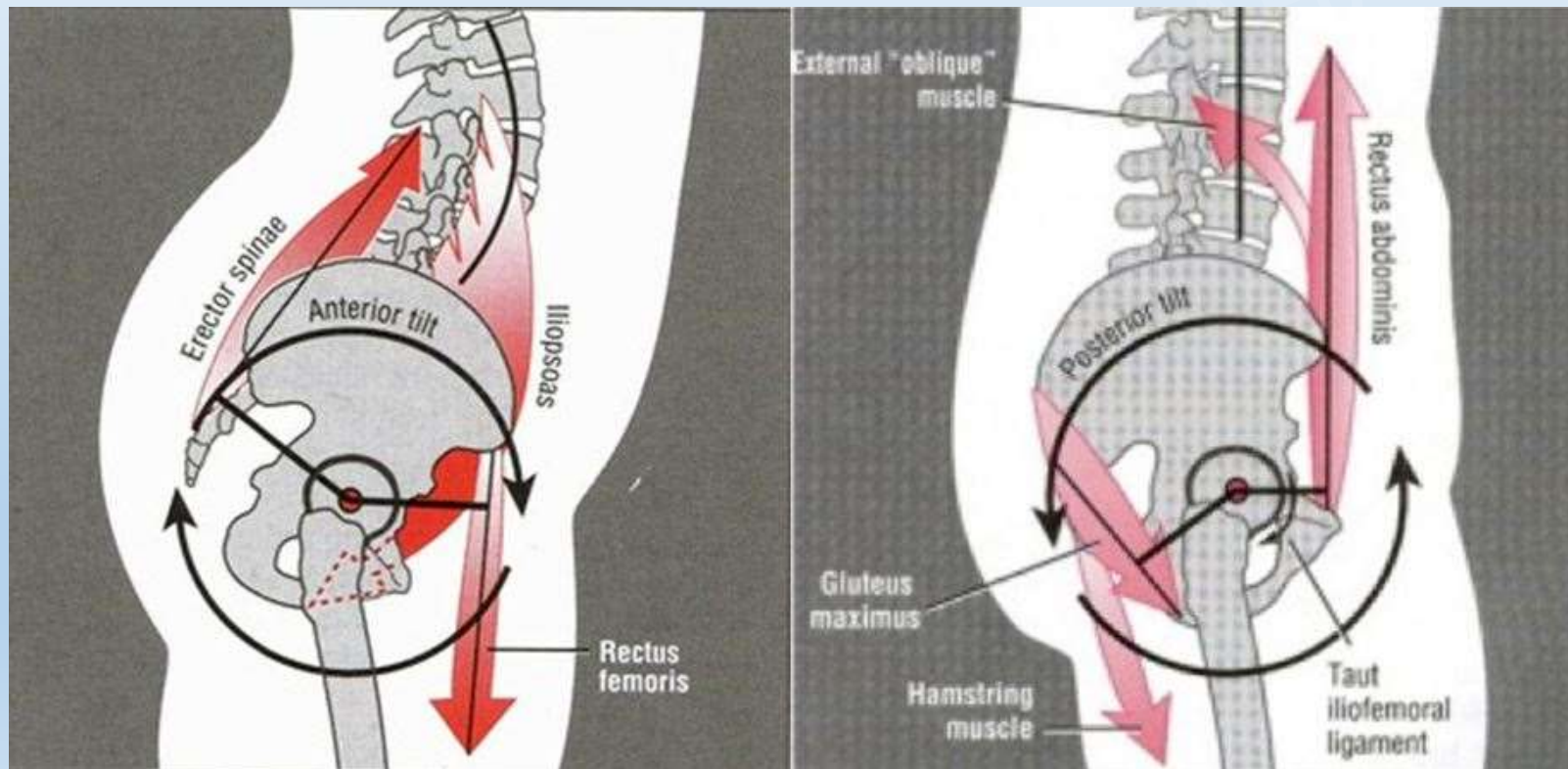


- Iliopsoas



Alt Ekstremit

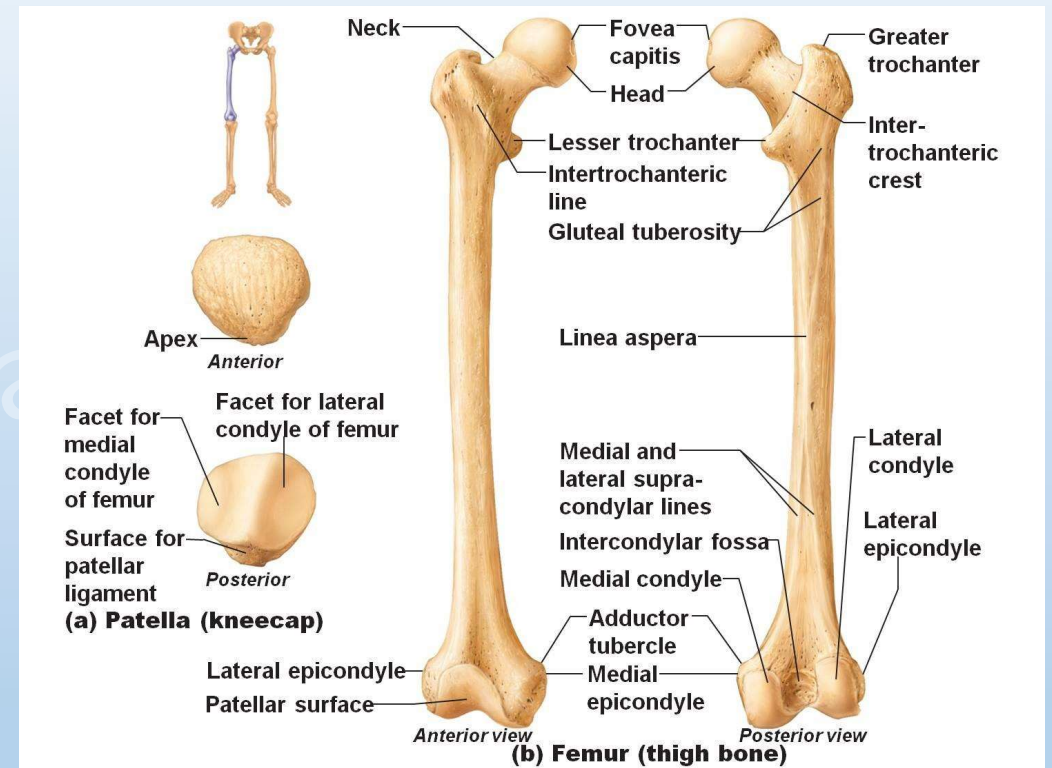
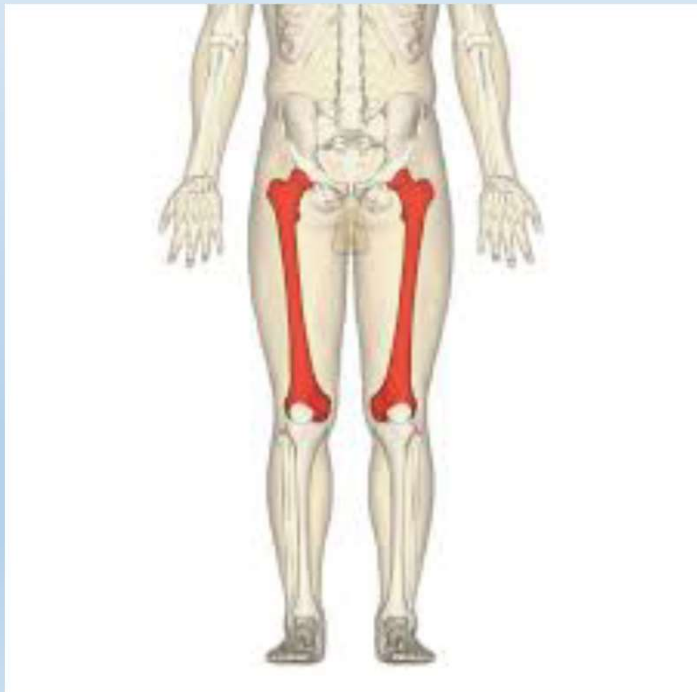- Anterior ve Posterior Tilt



Alt Ekstremit

Uyluk bölgesi kemiği:

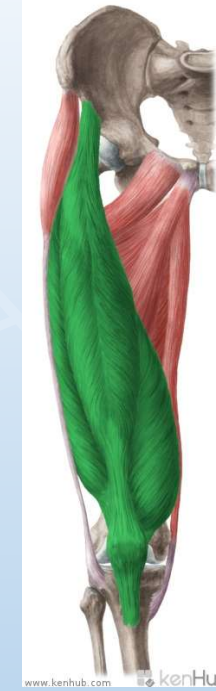- Femur



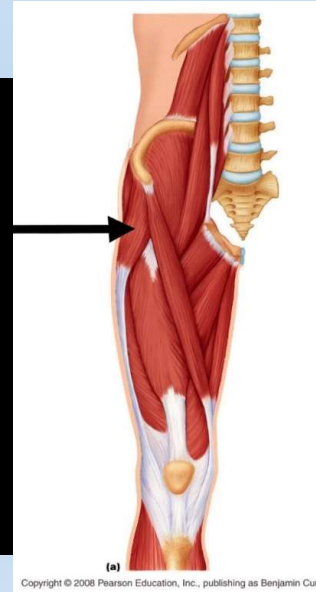
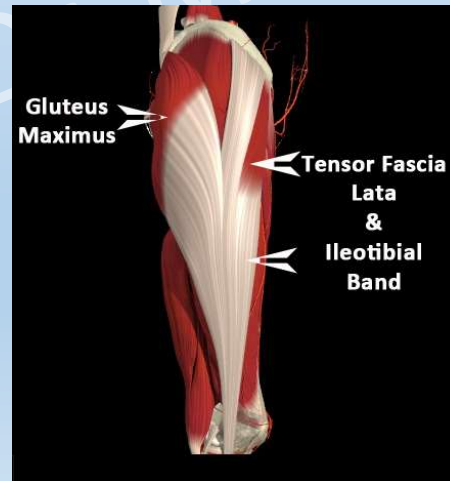
Alt Ekstremit

Uyluk bölgesindeki bazı kaslar:

- Quadriceps femoris



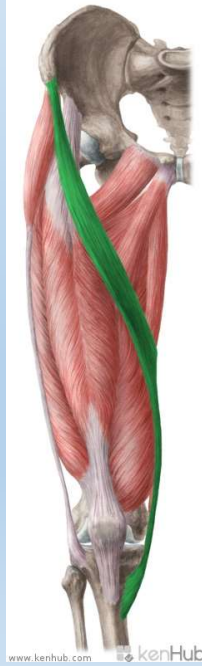- Tensor fasciae latae



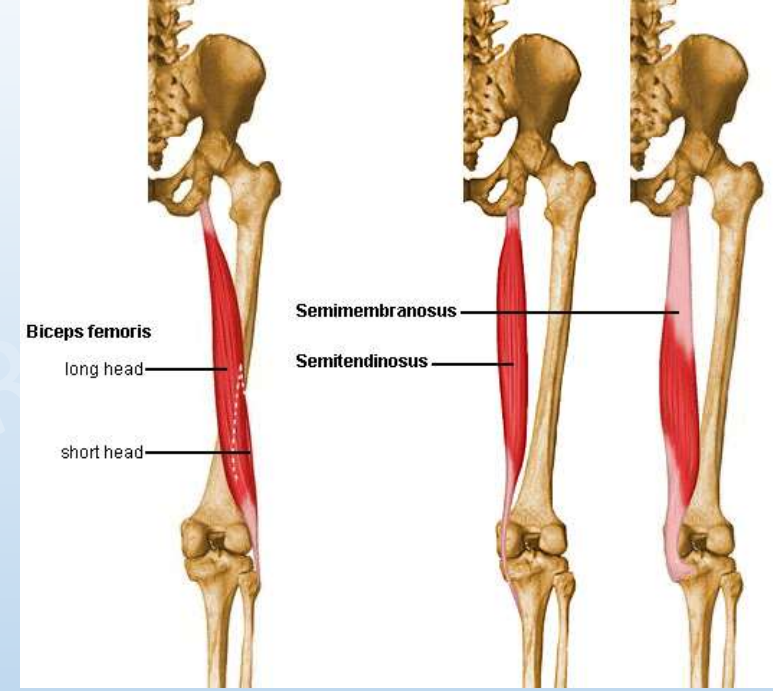
Alt Ekstremit

Uyluk bölgesindeki bazı kaslar:

- Hamstring Kasları:



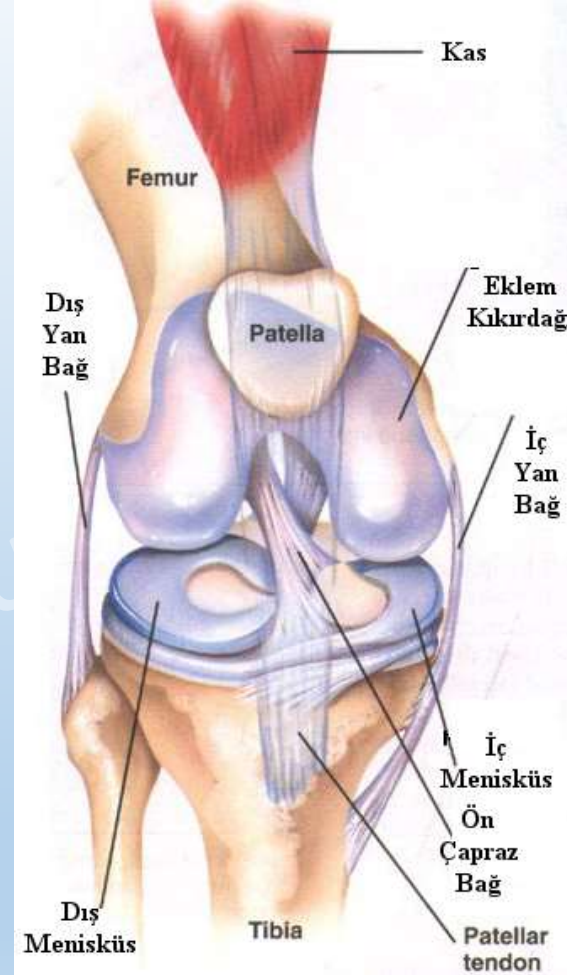
- Sartorius



Alt Ekstremitte

Diz bölgesi kemiđi:

- Patella

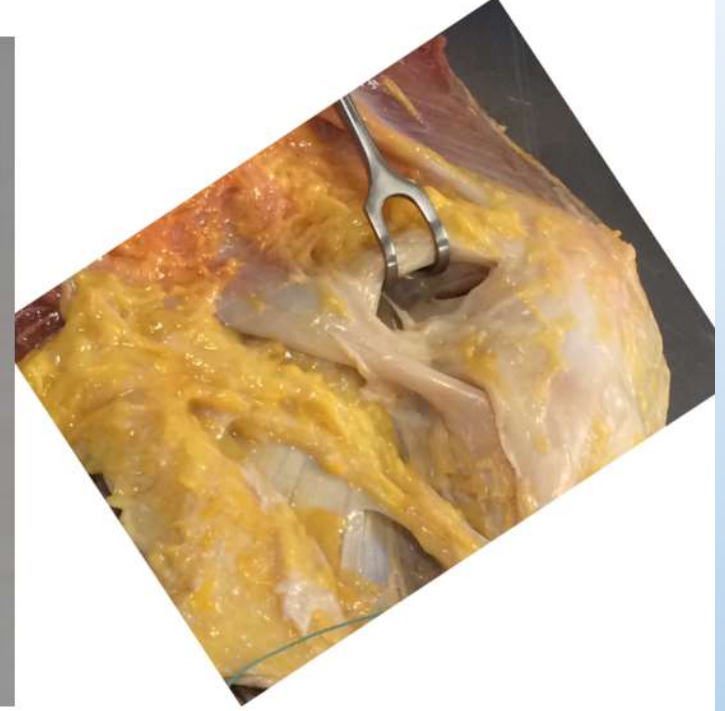
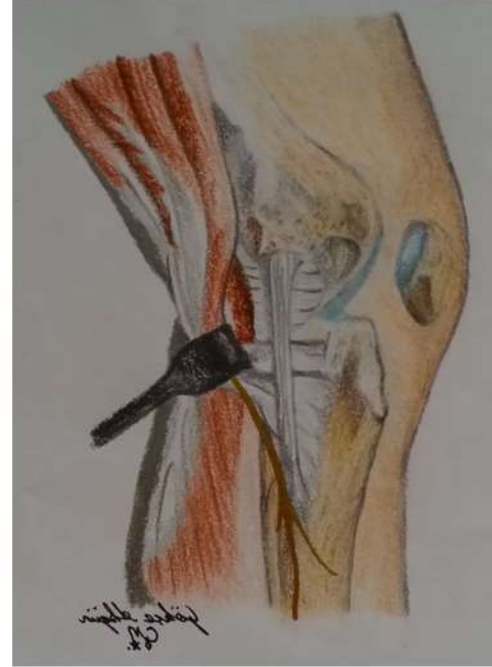

- <https://www.youtube.com/watch?v=wylJw034ssA>

Alt Ekstremitte

4 ana diz bađı:

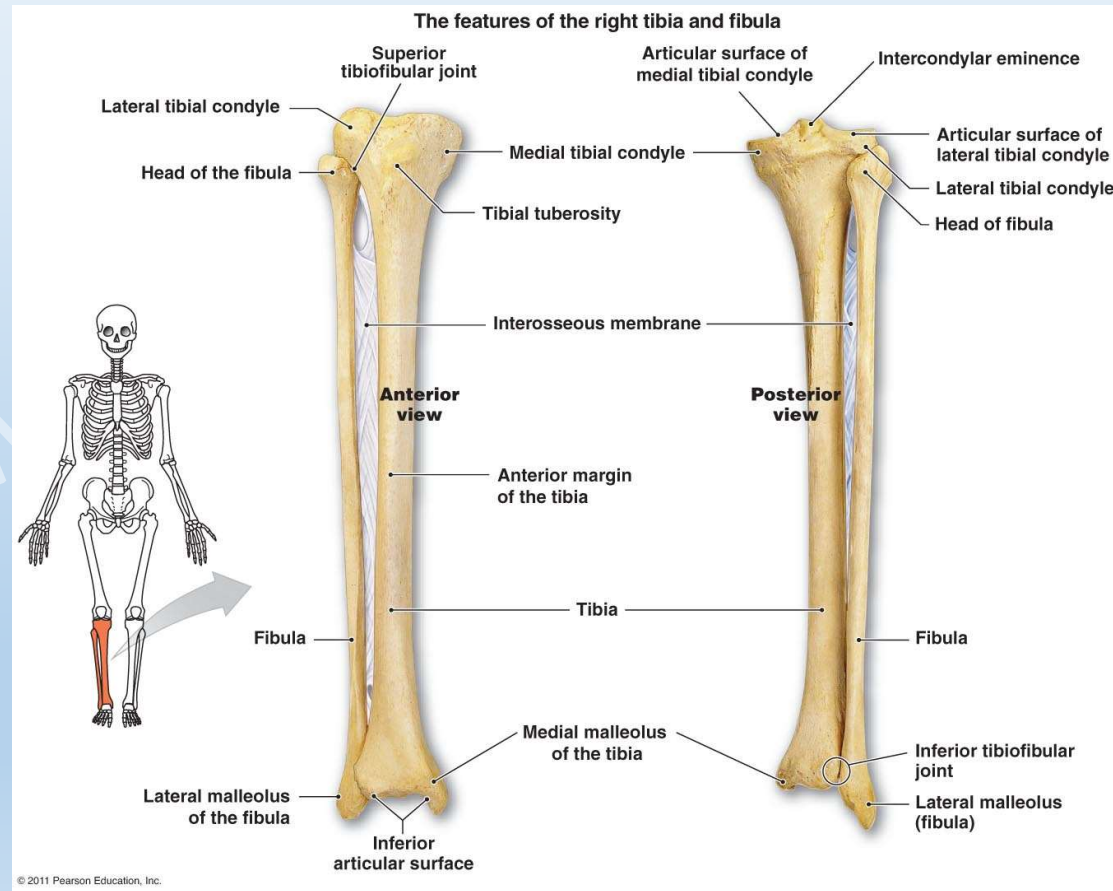
- ACL = Ön apraz bađ
- PCL = Arka apraz bađ
- MCL = İ yan bađ
- LCL = Diř yan bađ



Alt Ekstremité

Bacak bölgesi kemikleri:

- Tibia
- Fibula



Alt Ekstremit

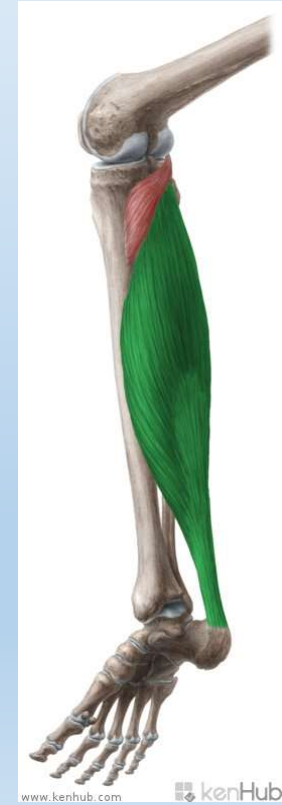
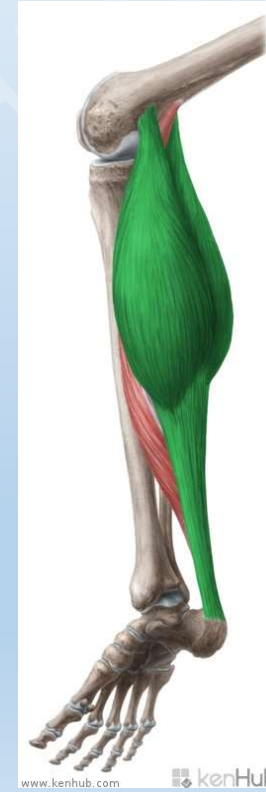
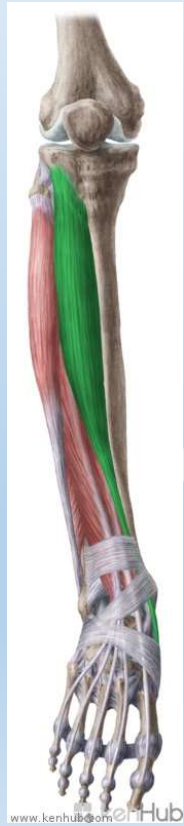
Bacak bölgesindeki bazı kaslar:

- Tibialis anterior

- Extensor digitorum longus

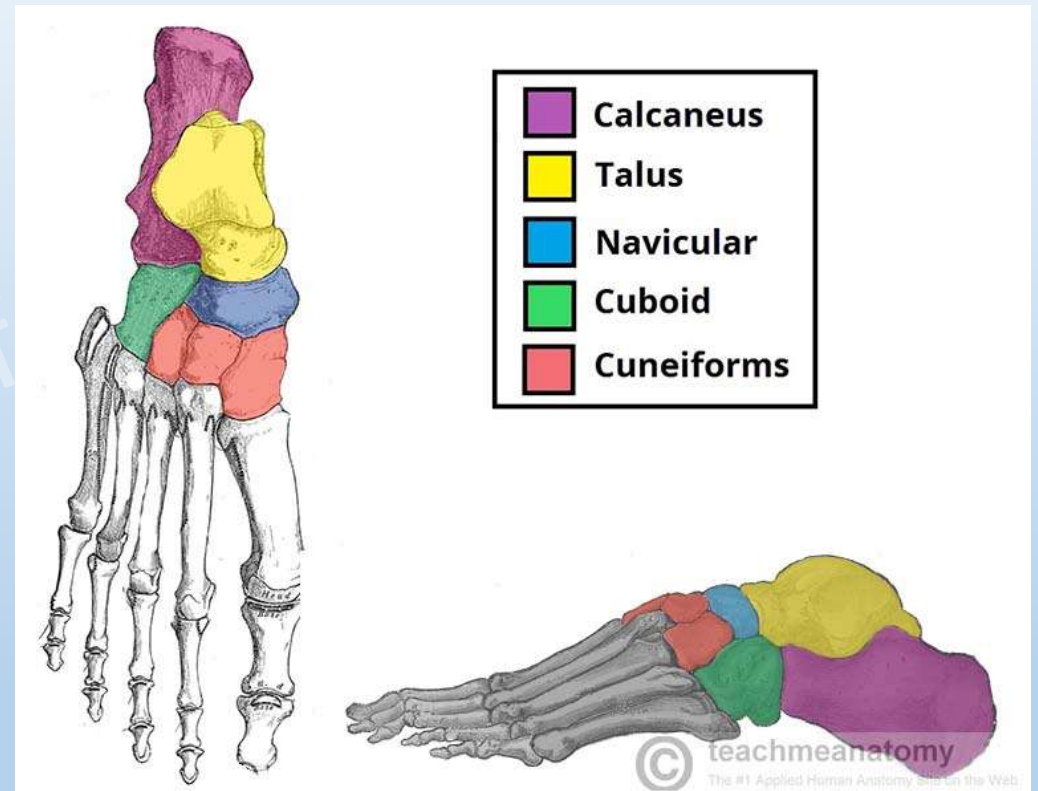
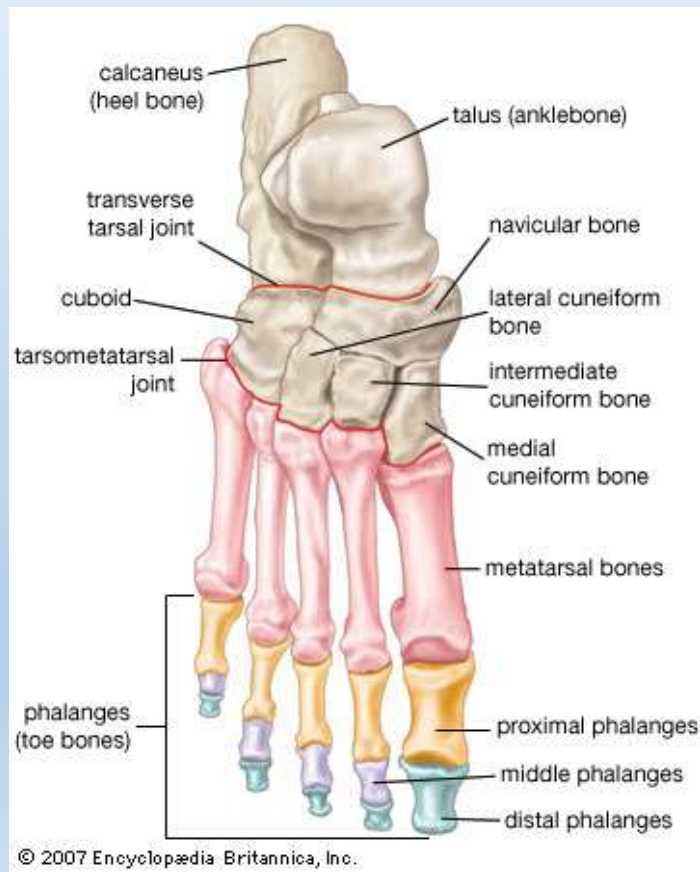
- Gastrocnemius

- Soleus



Alt Ekstremit

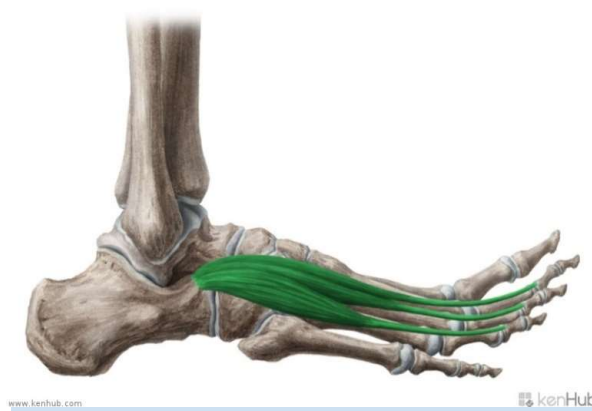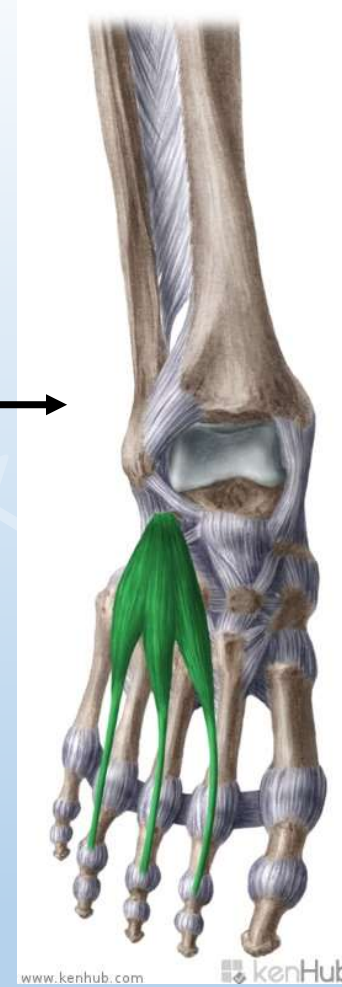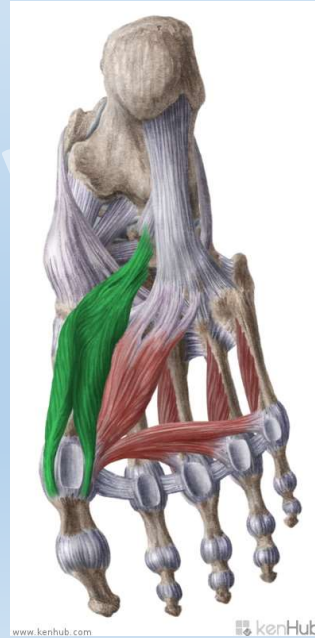
Ayak bölgesi kemikleri:



Alt Ekstremit

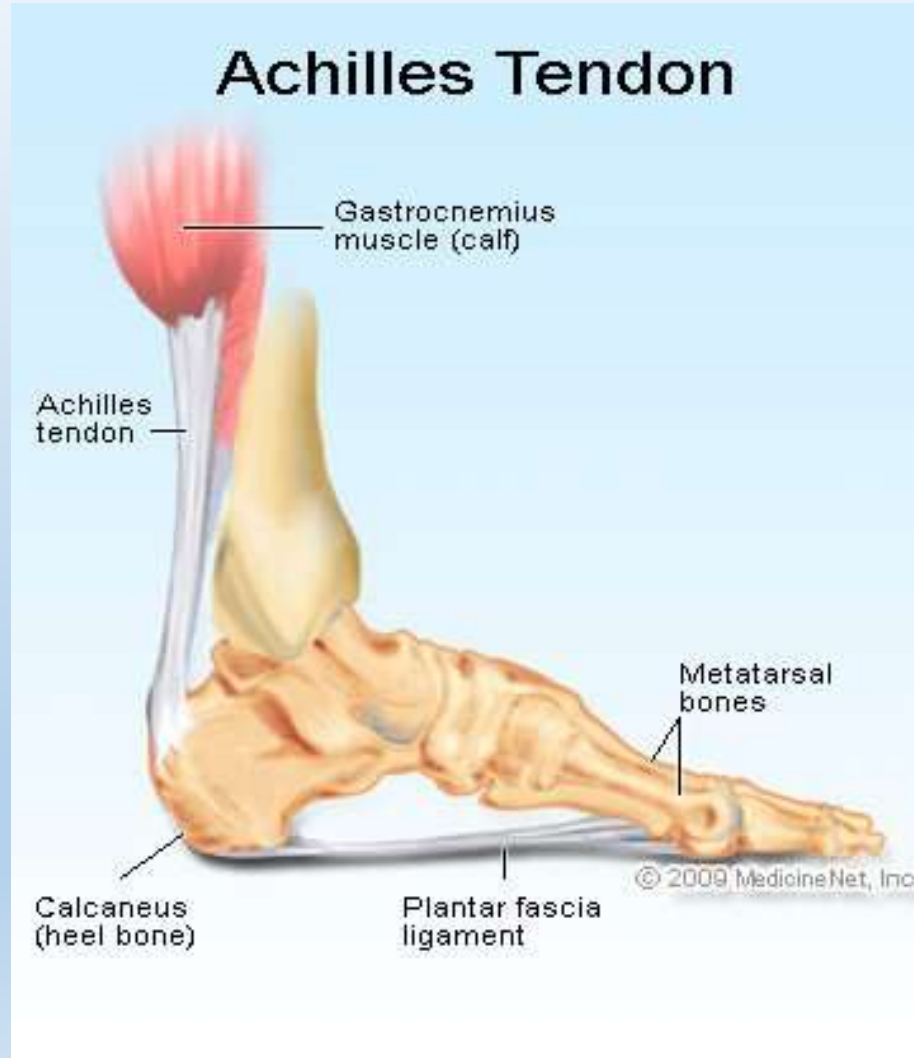
Ayak bölgesindeki bazı kaslar:

- Extensor digitorum brevis



Alt Ekstremit

- Aşil
- Plantar fasya



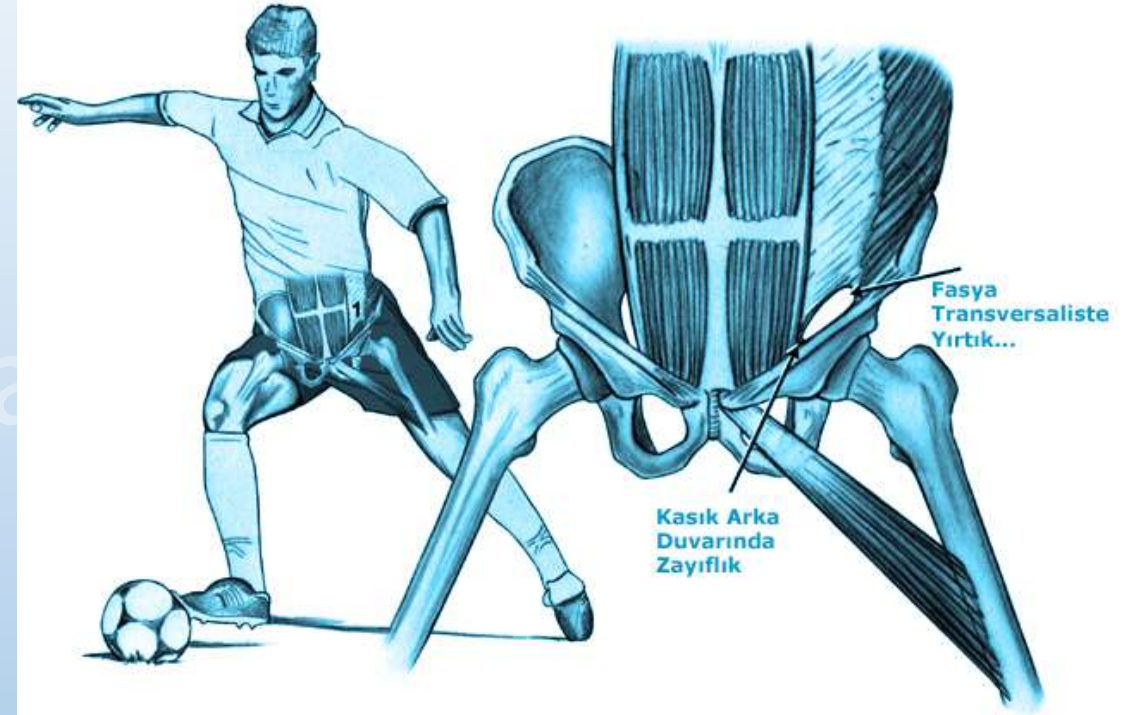
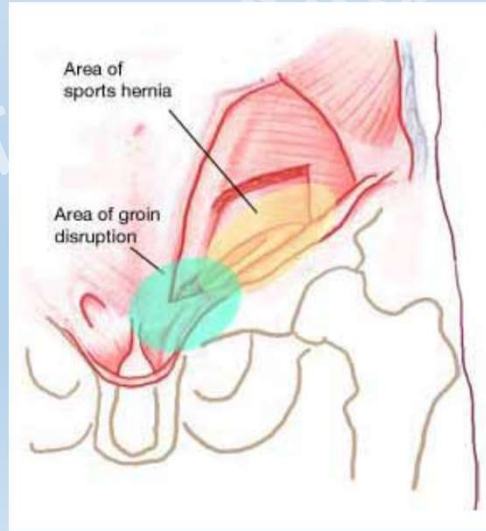
Prof. Dr.

Alt Ekstremitte Yaralanmaları

Pelvis bölgesindeki bazı yaralanmalar:

1. Sporcu kasık ağrısı

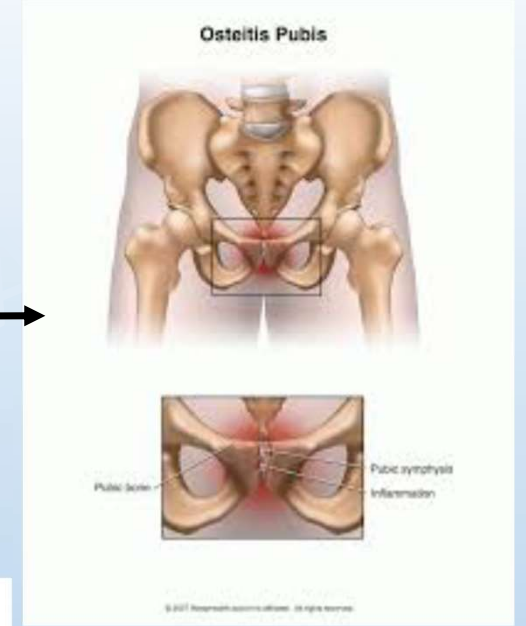
2. Sporcu fitiği



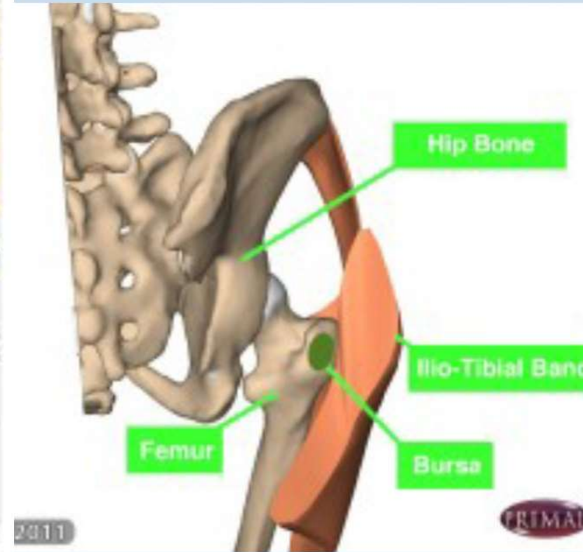
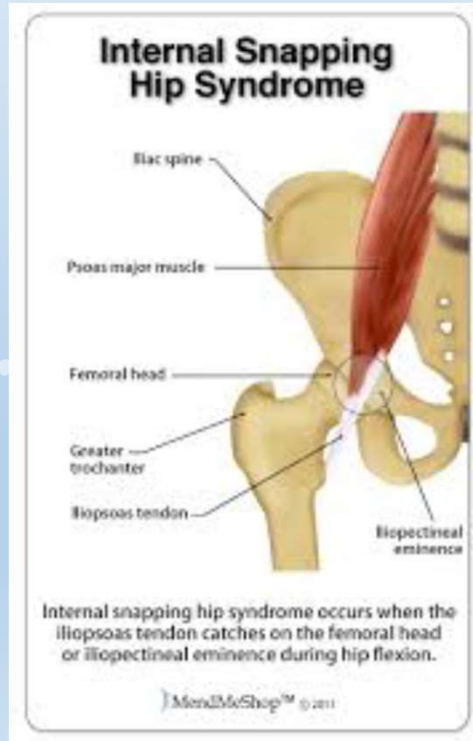Alt Ekstremitte Yaralanmaları

Pelvis bölgesindeki bazı yaralanmalar:

3. Periostit



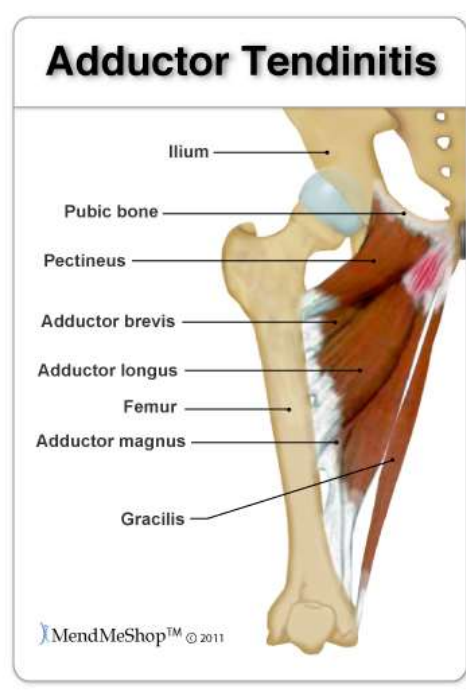
4. Snapping hip



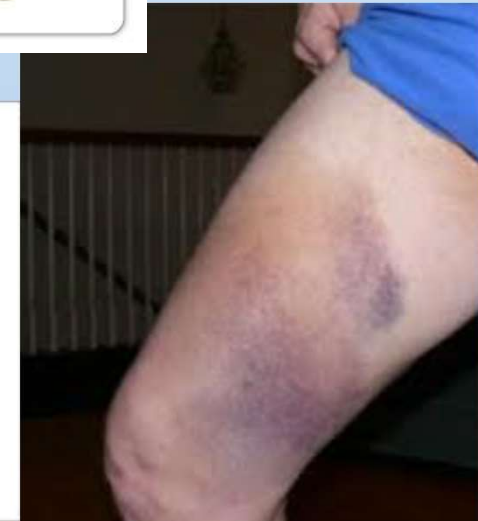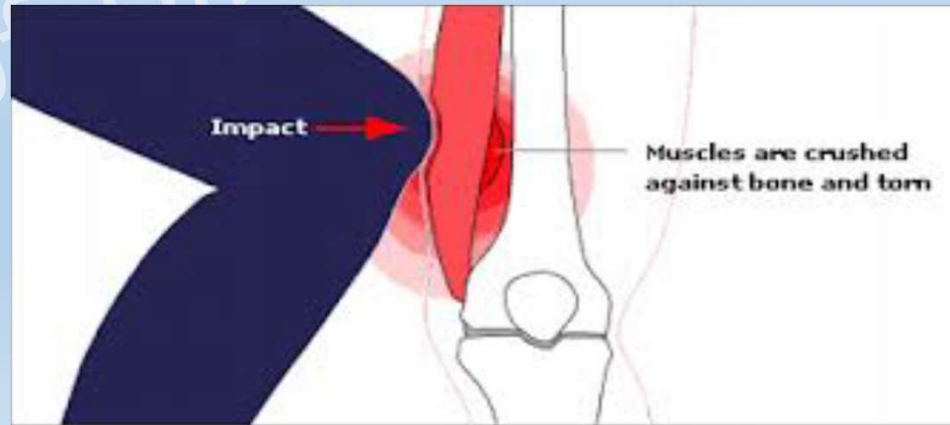
Alt Ekstremitte Yaralanmalar

Uyluk bölgesindeki bazı yaralanmalar:

1. Adduktor tendinit



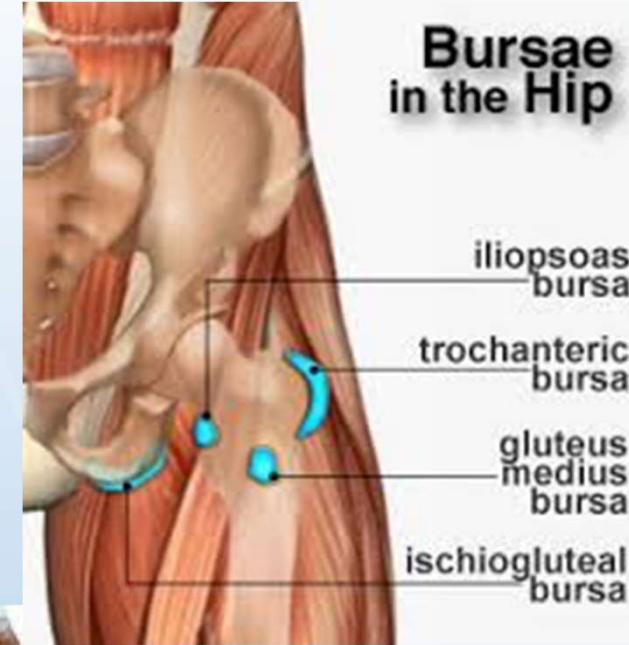
2. Quadriceps kontüzyonu



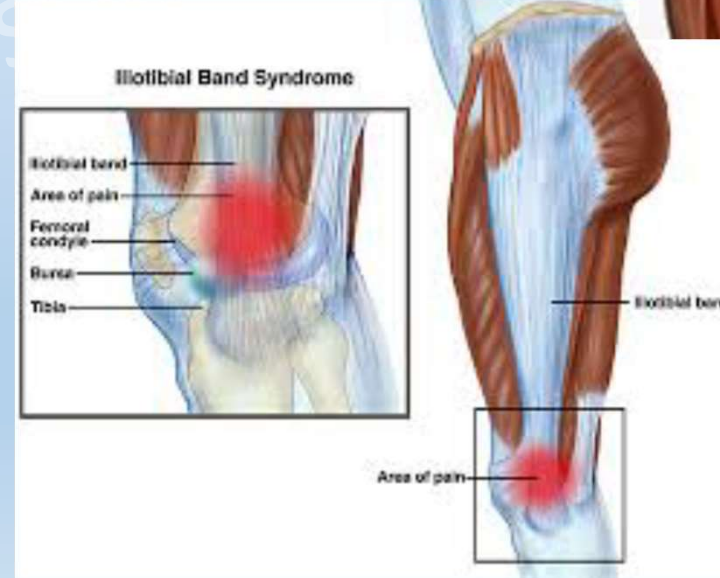Alt Ekstremitte Yaralanmaları

Uyluk bölgesindeki bazı yaralanmalar:

3. Uyluk bölgesi bursitleri



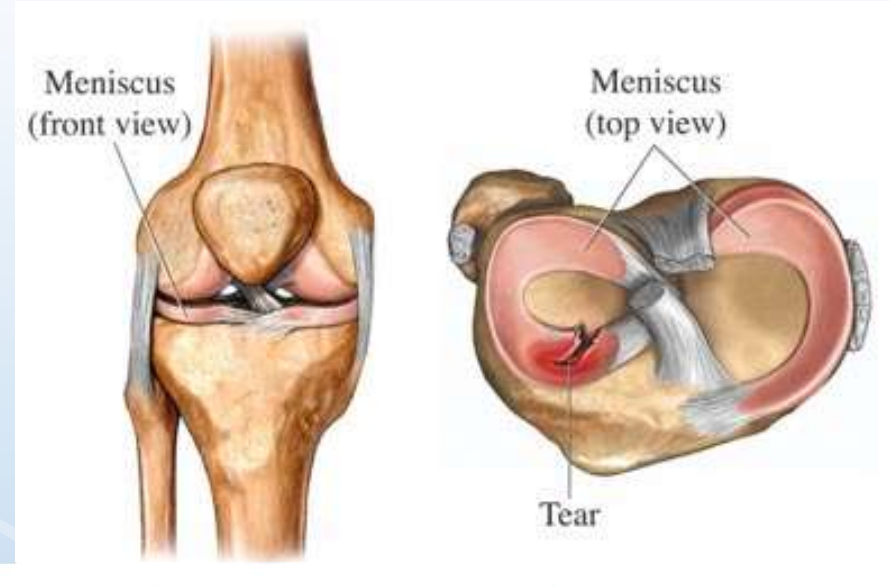
4. İliotibial band sürtünme sendromu



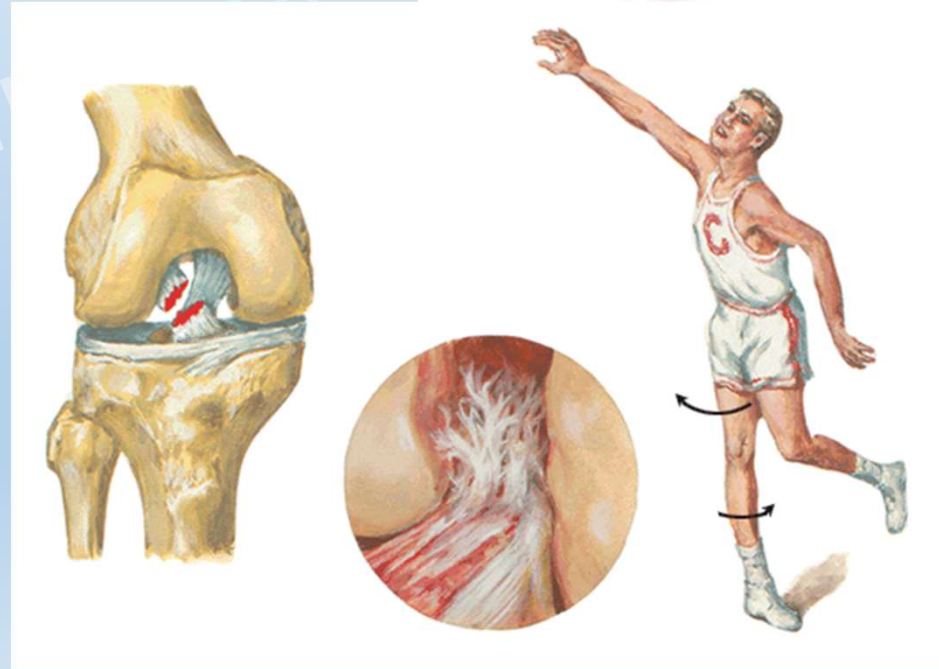
Alt Ekstremitte Yaralanmaları

Diz bölgesindeki bazı yaralanmalar:

1. Menisküs Yaralanmaları



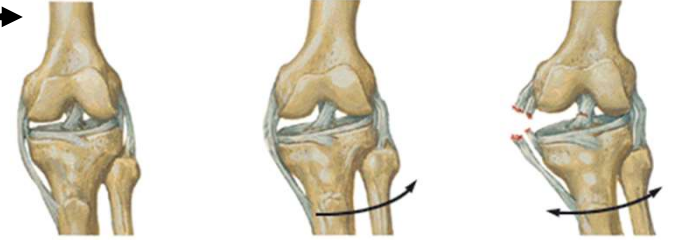
2. Ön Çapraz Bağ Yaralanması



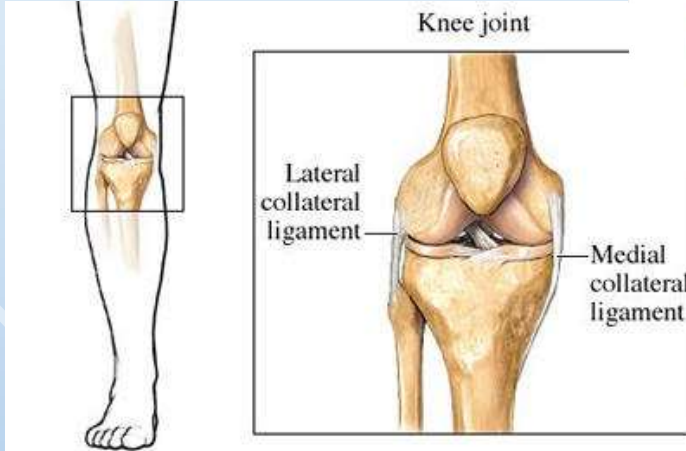
Alt Ekstremitte Yaralanmaları

Diz bölgesindeki bazı yaralanmalar:

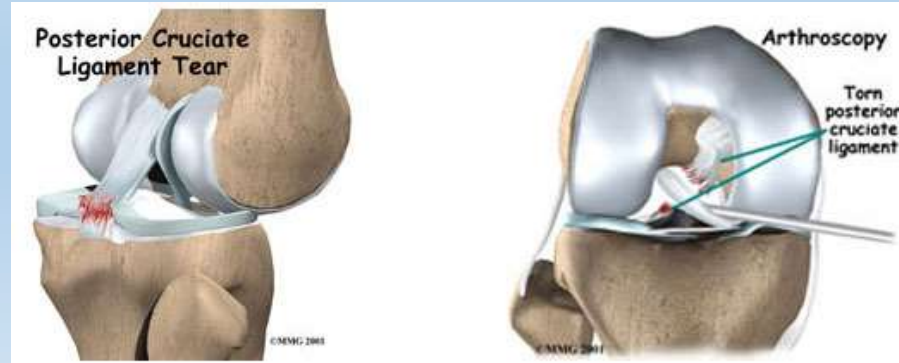3. İç yan bağ yaralanması



4. Dış yan bağ yaralanması



5. Arka çapraz bağ yaralanması



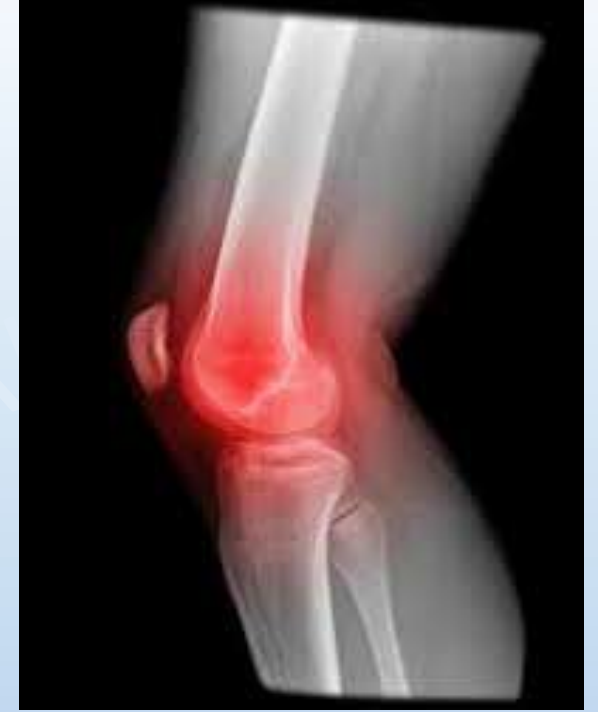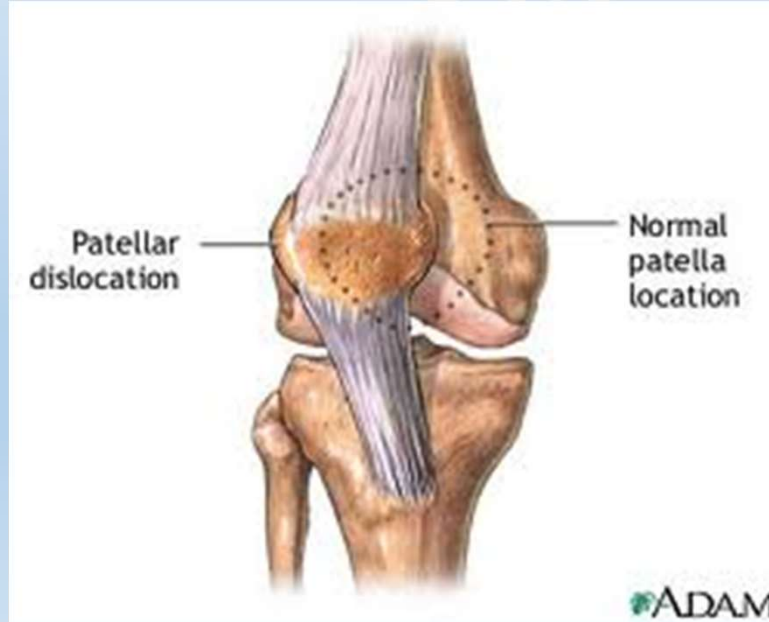Prof. Dr. M

Alt Ekstremitte Yaralanmaları

Diz bölgesindeki bazı yaralanmalar:

6. Patellofemoral ağrı sendromu (Diz önü ağrısı)


7. Patella çıkığı



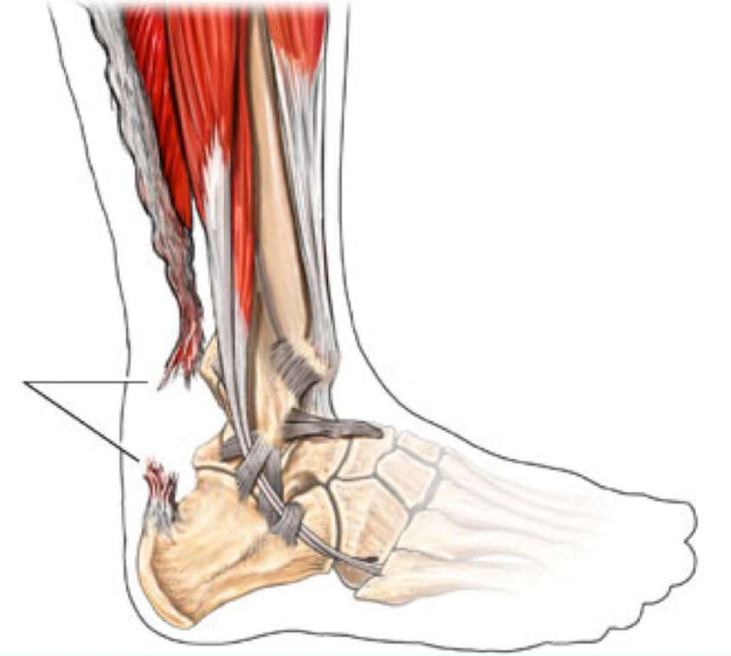
Alt Ekstremitte Yaralanmaları

Ayak bileđi bölgesindeki bazı yaralanmalar:

1. Aşil yaralanmaları

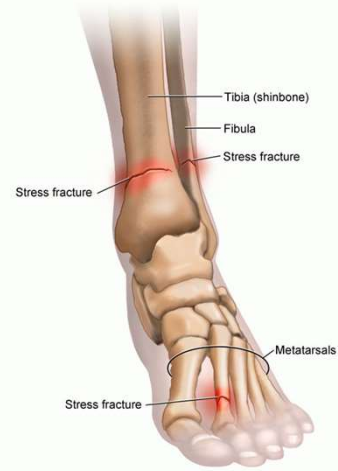

Kopmuş
(Rüptüre) Aşil
Tendonu



2. Stres Kırıkları

Stress Fractures of the Leg and Foot



© 2007 RelayHealth and/or its affiliates. All rights reserved.

Alt Ekstremit

Ayak bölgesindeki bazı yaralanmalar:

1. Plantar Fasiit
2. Jones Kırığı

